

EARLY SURGERY AFTER CORONARY REVASCULARIZATION: A FINE LINE BETWEEN BLEEDING AND THROMBOSIS

De Biase C, Capuano E, De Luca S, D'Anna C, Luciano R, Piscione F¹, Trimarco B, Galasso G*

Department of Advanced Biomedical Sciences, "Federico II" University of Naples, Italy

¹Department of Medicine and Surgery, University of Salerno, Salerno, Italy

e-mail: gengalas@unina.it

*Correspondence:

Gennaro Galasso, MD

Department of Advanced Biomedical Sciences,

"Federico II" University of Naples,

Via Pansini 5, 80131 Naples, Italy

e-mail: gengalas@unina.it

Abstract:

Management of PCI patients undergoing early surgery is still a matter of debate. Noteworthy, PCI patients require a dual antiplatelet therapy (DAPT), with aspirin and a thienopyridine (clopidogrel, prasugrel, ticagrelor), because of the high risk of stent thrombosis (ST), myocardial infarction (MI) and death, especially within the first month. Indeed, the number of surgical interventions after PCI is actually increasing, and physicians are looking for the best antiplatelet therapy management, in order to reduce both, bleeding and thrombosis risk. In this paper, current guidelines therapy management and new optional strategies to reduce the cardiovascular risk, related to early surgery, are discussed.

Keywords: non-cardiac surgery, percutaneous coronary intervention, antiplatelet therapy, stent thrombosis, bleeding

INTRODUCTION

Percutaneous coronary intervention (PCI) is an invasive non-surgical cardiovascular intervention, widely used for the treatment of coronary artery disease (CAD), with high rates of success and low rates of complications (1-3). Since its introduction in the clinical scenario, "new devices" have replaced, or served as adjuncts, to the first plain old balloon angioplasty (POBA), including bare-metal stents (BMS) and drug-eluting stents (DES), with improved efficacy and safety profile of percutaneous revascularization, and consequent transition from the

balloon PCI alone to the PCI with stenting (4). However, because of the high thrombotic risk following stent deployment, patients undergoing PCI with stenting require a specific dual antiplatelet therapy (DAPT), with aspirin and a P2Y₁₂ receptor antagonist (clopidogrel, prasugrel or ticagrelor), as best medical treatment for preventing thrombosis (5). According to the current PCI guidelines (6-9), in patients with stable CAD, DAPT is strongly recommended for at least 1 month after a BMS deployment or POBA, and up to 6-12 months after a DES, in order to reduce the risk of ischemic events following PCI, including stent thrombosis (ST), myocardial infarction (MI) and death (10-13). Nevertheless, it should be considered that, after acute coronary syndromes (ACS) (ST-elevation-MI, Non-ST-elevation-MI, unstable-angina), the DAPT duration required is at least up to 12 months. Nowadays, there is a prevalence of premature withdrawal of DAPT between 10% and 50% of patients underwent PCI. One of the main reasons of DAPT disruption is the need of early surgery, defined as surgical procedure occurring within 6 weeks after BMS or within 12 months after DES deployment (14). Interestingly, surgical interventions are required within 2 years in approximately 5% to 15% of patients undergoing PCI (15). Moreover, several studies confirmed that between 4% and 8% of PCI patients require non-cardiac surgery within 1 year from revascularization (16-20). Thereby, the drugs management of patients who need surgery after PCI remains one of the most debated topics. This is relevant not only for interventional cardiologists, but also for general cardiologists, surgeons, anesthesiologists, and primary care physicians, especially because they have to define and to face the life threatening ischemic and bleeding risk (15).

Indeed, surgical interventions are associated with a high bleeding risk in patients on DAPT, thus an early interruption of antiplatelet therapy is often required. Otherwise, the premature discontinuation of DAPT exposes patients to the risk of thrombotic consequences, further increased by the pro-inflammatory and pro-

thrombotic effects of surgery itself (higher platelets reactivity, coagulation proteins, fibrinogen levels and anemia or traumatic basal conditions). Current guidelines regarding PCI and surgery (21), suggest interrupting thienopiridine 5 (clopidogrel and ticagrelor) or 7 (prasugrel) days before surgery, without aspirin withdrawal, with exception for intracranial surgery or transurethral prostatectomy. However, the decision to early interrupt, one or both antiplatelet agents, depends on the evaluation of the individual thrombotic/bleeding risk. The aim of this review is to get more inside the therapeutic strategies for CAD patients requiring surgery after PCI with stenting.

ISCHEMIC COMPLICATIONS IN SURGICAL PATIENTS WITH PREVIOUS PCI

In PCI patients, there is a higher thrombotic risk, and the majority of thrombotic complications occur when metal stent strut and/or polymeric surface are not completely healed. Noteworthy, this high risk of thrombus formation is particularly harmful in a surgical setting, considering the prothrombotic and inflammatory blood properties, the increased levels of cytokines, neuroendocrine inflammatory mediators, platelet counts/adhesiveness, and the impaired fibrinolysis in patients requiring surgery (Tab. 1) (22-24). In particular, ST represents the main potentially catastrophic event that most commonly occurs within the first month after stent implantation. The causes of ST have been carefully investigated, and it is usually related to some specific clinical and angiographic features as reported in Fig. 1 (25-29). A new standard definition of ST was recently proposed by the Academic Research Consortium (ARC), in order to compare the true rates of ST across different trials and registries (Tab. 2) (30). However, in addition to the above-mentioned independent risk factors of thrombotic events, some evidence demonstrate that the premature discontinuation of DAPT represents the main risk factor for ST after BMS (31) or DES (11), and the rebound platelet reactivity after discontinuation of antithrombotic drugs, has been advocated to induce the increased thrombotic risk in PCI patients undergoing surgery (32, 33). Indeed, surgery represents the second cause of early DAPT discontinuation within 1 year (21%) (15). There are several studies updating the ischemic perioperative complications in patients undergoing early surgery after PCI with BMS (16, 34-37) or DES (10, 18, 38-41). Table.1: variables associated to pro-thrombotic state in PCI patients undergoing non-cardiac surgery.

The emphasis on DAPT cessation as the trigger for early ischemic events in PCI patients has been recently

<ul style="list-style-type: none"> - ACUTE CORONARY SYNDROME - RENAL DYSFUNCTION - DIABETES - ADVANCED AGE - HYPERCOAGULABLE STATES (E.G. ANEMIA, MALIGNANCY, SURGERY) - LOW RESPONSE TO THIENOPIRIDINE - HYPERSENSITIVITY TO POLYMER - PERSISTENT HIGH PLATELET REACTIVITY - STENT UNDEREXPANSION - STENT OVERLAPPING - RESIDUAL DISSECTION AT THE STENT EDGE - TYPE C LESION - PLAQUE RUPTURE - DELAYED STENT STRUT HEALING - HIGH LEVELS OF FIBRINOGEN AND COAGULATION PROTEINS

Table 1. Pro-thrombotic features in surgical setting

challenged. A large retrospective study analyzed 41,989 surgical interventions occurring within 24 months after stent implantation (42). Furthermore, the "Patterns of non-adherence to Antiplatelet Regimens In Stented patients" (PARIS) registry, analysed whether, the clinical circumstances and reason for discontinuation of DAPT, may have an impact on the cardiovascular risk that follows PCI (43). Interestingly, this registry explored carefully the underlying context in which antiplatelet treatment was discontinued, and patients were stratified into different categories, according to physician-recommended DAPT discontinuation, surgery related brief DAPT interruption, and early DAPT disruption due to non-compliance or bleedings. Surprisingly, physician-guided discontinuation, the most common cause of DAPT withdrawal (40.8% within 2 years), was associated with a significant lower risk of major adverse cardiac events (MACE), probably due to treatment bias in very low thrombotic risk patients. Moreover, brief interruption, occurring in 10.5% of patients for a mean of 6 days, was not associated with an increased rate of thrombotic events, while early disruption, occurring in 14.4% of patients, was associated with a substantial increased risk of MACE, particularly within the first month after PCI. Moreover, the registry reported that, the majority of adverse events occurred while patients were on DAPT, while DAPT disruption did not influence the overall cardiac outcome. Accordingly, a previous study by Reddy et al. (35)

showed that discontinuation of antiplatelet therapy was

ARC STENT THROMBOSIS CLASSIFICATION	
<p>Definite: symptoms suggestive of ACS and angiographic confirmation of ST.</p> <p>Probable: any unexplained death within 30 days or target vessel MI, without angiographic confirmation of ST.</p> <p>Possible: any unexplained death after 30 days.</p>	<p>Early: 0-30 days post stent implantation:</p> <ul style="list-style-type: none"> - Acute: <24 hours - Subacute: 1-30 days <p>Late: >30 days</p> <p>Very late: >12 months</p>
<p>ARC: Academic Research Consortium; ACS: Acute Coronary Syndrome; ST: Stent Thrombosis; MI: Myocardial Infarction.</p>	

not associated with perioperative MACE in 56 patients with prior bare-metal stenting.

Table 2. ARC stent thrombosis classification

On the whole, these findings are consistent with other studies suggesting that early DAPT interruption before surgery is not absolutely harmful, if aspirin is continued throughout the surgical intervention, and thienopyridines are resumed as soon as possible after surgery (32, 44). However, whether this concept can automatically be translated to all PCI patients undergoing surgery, remains undefined. Indeed, investigation on the impact of DAPT disruption on the perioperative cardiovascular risk, should also consider the general individual risk profile, the type of CAD (ACS or stable CAD) and both, ischemic and bleeding risk, related to different surgical interventions.

BLEEDING COMPLICATION IN SURGICAL PATIENTS ON ANTIPLATELET THERAPY

Perioperative bleedings may occur as consequence of surgical procedures or as effect of antiplatelet drug treatment during surgery. Up to date, the causes of bleedings are often a matter of debate (45). Otherwise, there are some surgical procedures that do not increase the risk of bleeding, but that can be associated with bleedings if antithrombotic medications are in use before surgery. The American College of Chest Physicians guidelines for the perioperative management of antithrombotic therapy, identified a group of surgical interventions associated with

high bleeding risk in the setting of perioperative anticoagulant and antithrombotic therapy (46), including vascular, visceral and transbronchial surgery. Nevertheless, minor surgical interventions like dental procedures, cataract surgery, dermatologic interventions, as well as angiographic diagnostic procedures or diagnostic endoscopies, can be performed under full antiplatelet therapy, provided that no additional bleeding risk exists (47-49). A meta-analysis collecting 49,590 patients undergoing non-cardiac surgery, estimated that the incidence of bleeding complications, in patients on aspirin therapy, varies from 0% (e.g., in case of skin lesion excision or cataract surgery) up to 75% (e.g., in case of transrectal biopsy) (50). Indeed, aspirin does not increase the severity of bleeding, while influences the number of bleeding events, with exception for intracranial surgery and transurethral prostatectomy. On the other hand, further studies conducted in patients undergoing non-cardiac surgery, reported the increased rate of bleedings with perioperative continuation of both aspirin and P2Y₁₂ inhibitors (35, 36, 49). Therefore, it has been suggested the continuation of aspirin or thienopyridine alone, for secondary prevention in many surgical interventions (51). Nevertheless, in patients undergoing surgical procedures in closed anatomical space (e.g. intracranial neurosurgery, posterior chamber of the eye, medullary canal etc.) or if major bleedings are expected, it would rather be necessary to interrupt any kind of antiplatelet agent from 5 to 7 days before surgery (51). Anyway, also the best suitable choice of P2Y₁₂ inhibitors plays a role in the management of bleedings. New oral P2Y₁₂ inhibitor agents, prasugrel and ticagrelor, are correlated to major bleedings if compared to clopidogrel. Prasugrel, similar to clopidogrel, binds selectively and irreversibly to platelet P2Y₁₂ receptor, but has a much rapid and consistent platelet inhibition (52). However, the perioperative use of prasugrel is limited, because of the increased bleeding risk related to its irreversible platelets inhibition. Otherwise, this drug could be used after surgery considering its rapid and potent onset of platelets inhibition. Moreover, in the TRITON-TIMI-38 trial (53), patients with acute coronary syndromes (ACS), referred to coronary artery by-pass grafting (CABG) and randomized to receive prasugrel or clopidogrel, showed a reduction of ischemic events and a rate of TIMI major bleeding greater with prasugrel therapy. Ticagrelor, instead, is a non-thienopyridine agent that directly and reversibly inhibits P2Y₁₂ platelet receptor, with better results on platelet aggregation than clopidogrel. The PLATO study (54), a trial comparing ticagrelor versus clopidogrel in ACS

patients referred to invasive or non-invasive intervention, demonstrated MACE and ST rates reduction, and a similar

rate of TIMI major bleeding to clopidogrel, in patients undergoing CABG within 7 days after last drug intake.

Clinical and Angiographic predictors of ST

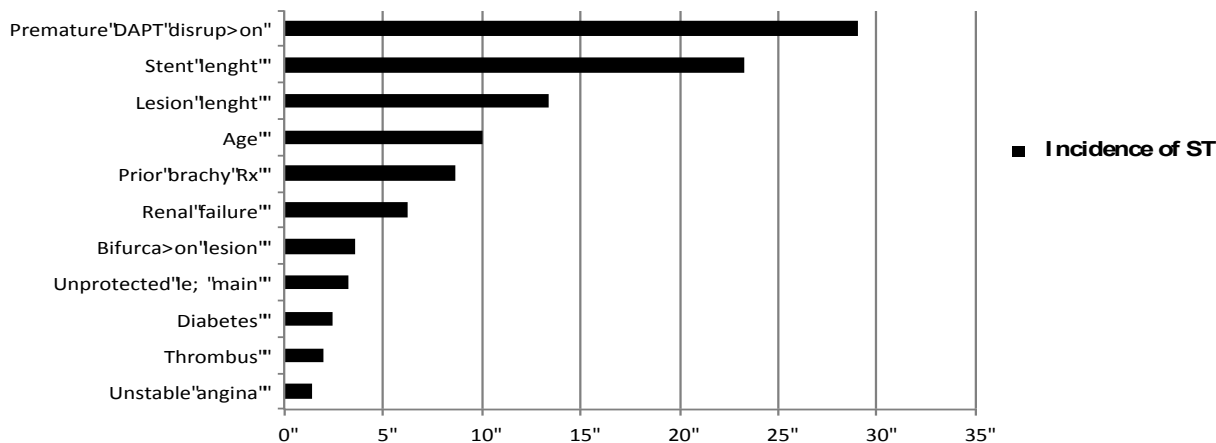


Figure 1: Incidence of stent thrombosis (%) related to clinical and angiographic factors (Adapted from Iakovu I. et al. *JAMA*. 2005 May 4;293(17):2126-30.)

Therefore, the advantage of ticagrelor in perioperative setting could be due to the short half life and to its reversibility (52). Current guidelines (55), thus recommend continuing aspirin during surgical procedures, while interrupting clopidogrel or ticagrelor 5 days before surgery, and prasugrel 7 days before surgery. However, in case of cardiac surgery, it is essential to consider the additional bleeding risk factors like heparinization, pump-induced platelet dysfunction and impaired fibrinolysis (56), which further influence the antithrombotic drugs management.

BRIDGING THERAPY

The perioperative antiplatelet therapy management usually requires the interruption of both aspirin and ADP receptor inhibitor. However, if DAPT is strictly required until surgical intervention, short-acting platelet antagonists should be considered, up to few hours before surgery, as "bridging" therapy. The rationale of the bridging therapy is to reduce the risk of perioperative bleedings, promising ischemic prevention both before surgery and in the early postoperative period, when many surgeons avoid to re-

introduce DAPT immediately because of the high bleeding risk. Unfractionated heparins or low molecular weight heparins (LMWH) are not optimal bridging agents, because endovascular thrombosis depends on platelets activation rather than on coagulation cascade (57). Otherwise, glycoprotein IIb/IIIa (GpIIb/IIIa) inhibitors, such as the synthetic peptides eptifibatid (58) or tirofiban (59), hold some characteristics of an ideal bridging agent, including rapid activity, potent antiplatelet effects and short effect duration, except abciximab, that causes a prolonged irreversible platelets aggregation inhibition, and thus should not be used perioperatively (60). However, there are few discordant studies about their efficacy as bridging drugs, and the role of GpIIb/IIIa inhibitors requires more investigations. In addition, the BRIDGE trial (61) recently considered the cangrelor, a reversible P2Y₁₂ receptor inhibitor, as an ideal bridging agent in patients undergoing coronary artery by-pass graft (CABG), showing that it is valuable in this specific clinical setting because of its intravenously administration, with rapid onset and offset. Whether these findings hold good also for other kind of non-cardiac surgical interventions, is still a hypothesis, but not a proof yet.

DEDICATED DEVICES

The introduction of second generation DES in the clinical practice, demonstrated a favourable safety profile in terms of low rate of ST and shorter DAPT duration, when compared to first generation DESs. Up to date, DESs are being used in high-risk lesions, even if several reports have suggested that they may be associated with delayed endothelialization, localized hypersensitivity reactions, and late ST (62-64). In the Efficacy of Xience/Promus Versus Cypher to Reduce Late Loss After Stenting (EXCELLENT) trial (65), 6-month DAPT did not increase the risk of target vessel failure at 12 months after DES, when compared to 2-month DAPT in stratified analyses of patients receiving everolimus- or sirolimus-eluting stents. In the Real Safety and Efficacy of 3 month dual-antiplatelet Therapy following Endeavor zotarolimus-eluting stent implantation (RESET) trial (66), a strategy of 3 month-DAPT following Endeavor zotarolimus-eluting stent, was found to be non-inferior in comparison with 12 month-DAPT following other DES, for the primary composite endpoint of cardiovascular death, MI, ST, target vessel revascularization (TVR), or bleeding at 12 months. Lastly, second-generation Xience-Prime and Xience-V everolimus-eluting stents, have recently gained the European CE Mark approval for the use with DAPT for at least 3 months, and the Resolute Integrity zotarolimus-eluting stent for 1 month, which represent the shortest DAPT duration for any major DES in Europe. Nowadays, several new devices that could overcome many limitations of BMS and DES, reducing the risk of ST and requiring shorter DAPT duration, have been developed, including DES with biodegradable polymer which combine the advantage of the early antisthenotic benefit of a standard DES and the long-term safety benefit of a BMS. Noteworthy, these new devices, thanks to advanced drug delivery systems and different struts, could be more suitable in patients referred to early surgery after PCI. Indeed, the newer polymer free stent CID OPTIMA new-generation DES, combines the patented polymer-free drug reservoir and the proven antithrombotic and prohealing integral carbofilm coating. The OPTIMA has no drug polymer, and the antiproliferative agent used (tacrolimus) (67), is carried directly on the stent outer surface and released inside the wall vessel (68). Two randomized studies investigated clinical outcome of Janus Flex TES implantation with shorter DAT duration, the JUPITER I study (69) and the

JUPITER II trial (70). Both trials demonstrated the safety of this device, without abruption of thrombotic events, despite only 2- or 6-months DAPT course, respectively. Furthermore, the Multicentre registry with Antiplatelet Treatment two–six months—MATRIX Study (71), a prospective, multicentre registry, investigated safety and efficacy of Janus Flex TES, at 12-months of follow-up in patients undergoing PCI, with a DAPT duration of 2 or 6 months. Results showed that Janus Flex coronary stenting, followed by short DAPT, is safe and feasible, with no difference between 2- and 6-month DAPT groups. Indeed, another safe and effective option in patients referred to PCI, with known or supposed low compliance to DAPT, or candidate to early surgery, is the Genous Bio-engineered-R stent (GRS) (72). The GRS feature is the ability of capturing circulating endothelial-progenitor cells (EPCs) from the blood stream, ensuring an early stent strut endothelialization (73, 74). Interestingly, a pilot study conducted in patients who need coronary revascularization before undeferrable non-cardiac surgery, showed that, after an average antiplatelet therapy time of 15 days, there were no cardiac events both in the perioperative period and at 30-day follow-up (75). Accordingly, the Antiplatelet therapy after Genous EPC-capturing coronary stent implantation — ARGENTO Study (76) investigated the safety and efficacy of GRS with ≤ 15 -day or > 15 -day DAPT in patients undergoing PCI, with known or expected low compliance to long-term DAPT. No significant differences were reported between different DAPT timing groups, in terms of efficacy and safety end-points (the composite of cardiac death, any myocardial infarction, target vessel revascularization and stent thrombosis). On the whole, these new devices could represent an optional strategy for coronary revascularization in patients who need early surgical intervention because of their shorter DAPT required, but further dedicated studies need to confirm this hypothesis.

CONCLUSIONS

Perioperative management of antiplatelet drugs in PCI patients is still a critical topic. However, in case of elective surgery, DES should be avoided, unless a surgery delays up to 12 months following DES deployment. Otherwise, CABG, BMS or POBA should be considered (Fig.2). In patients with semi-urgent surgery, the decision to early interrupt one, or both, antiplatelet drugs (at least 5-7 days pre-surgery), should undergo multidisciplinary consultation, with the evaluation of the

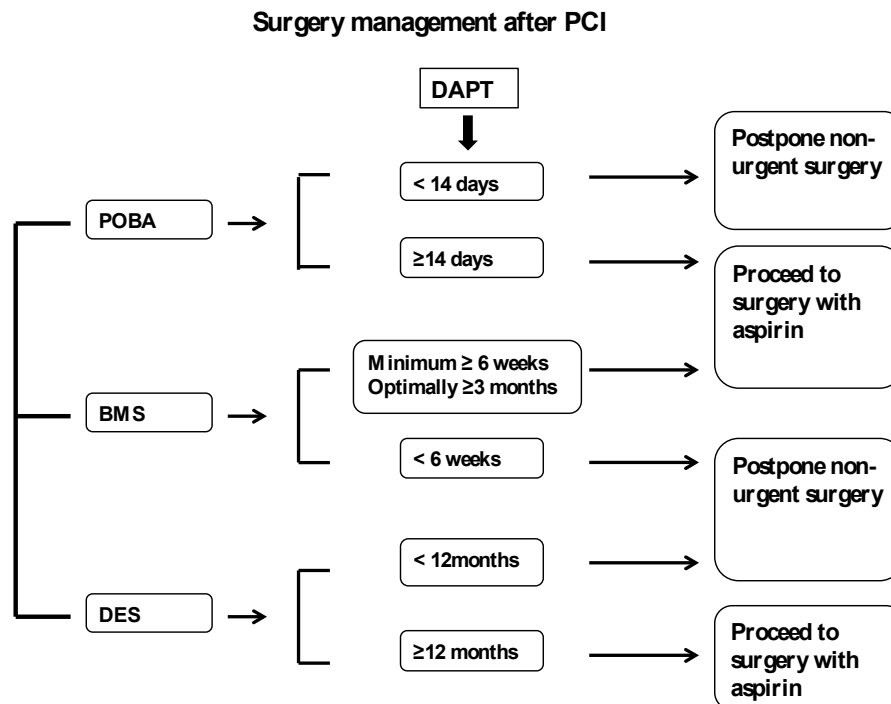


Figure 2: Previous coronary revascularization and surgery management.

thrombotic and bleeding risk, according to the type of surgical intervention (low or high bleeding risk surgery). Nevertheless, emergent surgery should be performed with full antiplatelet therapy, despite the increased bleeding risk. Indeed, clinical practice guidelines support preventive strategies in order to reduce the risk of DAPT withdrawal in patients referred to surgery, including BMS implantation whenever possible. However, there are new optional strategies to manage PCI patients referred to early surgery, such as the use of dedicated devices, with early healing and brief DAPT, or the perioperative administration of GpIIb/IIIa inhibitors, which represent a potential pharmacological strategy to avoid stent thrombosis and its dramatic effects, without increasing surgical bleedings. Up to date guidelines supply only few patient- and procedure-specific recommendations, in order to help physicians tailoring dedicated treatment strategies, in the setting of early surgery following PCI. Therefore, it is strictly required to consider type of surgical intervention and to balance safety and efficacy profiles of antiplatelets drugs, in this particular scenario.

REFERENCES

1. Steg PG, James SK, Atar D, Badano LP, Blomstrom-Lundqvist C, Borger MA, et al. ESC Guidelines for the management of acute myocardial

infarction in patients presenting with ST-segment elevation. *European heart journal*. 2012;33(20):2569-619.

2. Hamm CW, Bassand JP, Agewall S, Bax J, Boersma E, Bueno H, et al. ESC Guidelines for the management of acute coronary syndromes in patients presenting without persistent ST-segment elevation: The Task Force for the management of acute coronary syndromes (ACS) in patients presenting without persistent ST-segment elevation of the European Society of Cardiology (ESC). *European heart journal*. 2011;32(23):2999-3054.

3. Montalescot G, Sechtem U, Achenbach S, Andreotti F, Arden C, Budaj A, et al. 2013 ESC guidelines on the management of stable coronary artery disease: the Task Force on the management of stable coronary artery disease of the European Society of Cardiology. *European heart journal*. 2013;34(38):2949-3003.

4. Laskey WK, Kimmel S, Krone RJ. Contemporary trends in coronary intervention: a report from the Registry of the Society for Cardiac Angiography and Interventions. *Catheterization and cardiovascular interventions : official journal of the Society for Cardiac Angiography & Interventions*. 2000;49(1):19-22.

5. Piccolo R, Gioia GD, Niglio T, D'Anna C, Rosa RD, Strisciuglio T, et al. Pharmacotherapeutic considerations for the use of prasugrel and ticagrelor to reduce stent thrombosis in patients with acute coronary syndrome. *Angiology*. 2014;65(2):130-6.

6. Kolh P, Wijns W, Danchin N, Di Mario C, Falk V, Folliguet T, et al. Guidelines on myocardial

revascularization. *European journal of cardio-thoracic surgery* : official journal of the European Association for Cardio-thoracic Surgery. 2010;38 Suppl:S1-S52.

7. King SB, 3rd, Smith SC, Jr., Hirshfeld JW, Jr., Jacobs AK, Morrison DA, Williams DO, et al. 2007 Focused Update of the ACC/AHA/SCAI 2005 Guideline Update for Percutaneous Coronary Intervention: a report of the American College of Cardiology/American Heart Association Task Force on Practice Guidelines: 2007 Writing Group to Review New Evidence and Update the ACC/AHA/SCAI 2005 Guideline Update for Percutaneous Coronary Intervention, Writing on Behalf of the 2005 Writing Committee. *Circulation*. 2008;117(2):261-95.

8. Fleisher LA, Beckman JA, Brown KA, Calkins H, Chaikof E, Fleischmann KE, et al. ACC/AHA 2007 guidelines on perioperative cardiovascular evaluation and care for noncardiac surgery: a report of the American College of Cardiology/American Heart Association Task Force on Practice Guidelines (Writing Committee to Revise the 2002 Guidelines on Perioperative Cardiovascular Evaluation for Noncardiac Surgery): developed in collaboration with the American Society of Echocardiography, American Society of Nuclear Cardiology, Heart Rhythm Society, Society of Cardiovascular Anesthesiologists, Society for Cardiovascular Angiography and Interventions, Society for Vascular Medicine and Biology, and Society for Vascular Surgery. *Circulation*. 2007;116(17):e418-99.

9. Fleisher LA, Beckman JA, Brown KA, Calkins H, Chaikof EL, Fleischmann KE, et al. 2009 ACCF/AHA focused update on perioperative beta blockade incorporated into the ACC/AHA 2007 guidelines on perioperative cardiovascular evaluation and care for noncardiac surgery: a report of the American college of cardiology foundation/American heart association task force on practice guidelines. *Circulation*. 2009;120(21):e169-276.

10. McFadden EP, Stabile E, Regar E, Cheneau E, Ong AT, Kinnaird T, et al. Late thrombosis in drug-eluting coronary stents after discontinuation of antiplatelet therapy. *Lancet*. 2004;364(9444):1519-21.

11. Iakovou I, Schmidt T, Bonizzoni E, Ge L, Sangiorgi GM, Stankovic G, et al. Incidence, predictors, and outcome of thrombosis after successful implantation of drug-eluting stents. *JAMA : the journal of the American Medical Association*. 2005;293(17):2126-30.

12. Spertus JA, Kettelkamp R, Vance C, Decker C, Jones PG, Rumsfeld JS, et al. Prevalence, predictors, and outcomes of premature discontinuation of thienopyridine therapy after drug-eluting stent placement: results from the PREMIER registry. *Circulation*. 2006;113(24):2803-9.

13. van Werkum JW, Heestermans AA, Zomer AC, Kelder JC, Suttrop MJ, Rensing BJ, et al. Predictors of coronary stent thrombosis: the Dutch Stent Thrombosis Registry. *Journal of the American College of Cardiology*. 2009;53(16):1399-409.

14. Hawn MT, Graham LA, Richman JR, Itani KM, Plomondon ME, Altom LK, et al. The incidence and timing of noncardiac surgery after cardiac stent implantation. *Journal of the American College of Surgeons*. 2012;214(4):658-66; discussion 66-7.

15. Capodanno D, Angiolillo DJ. Management of antiplatelet therapy in patients with coronary artery disease requiring cardiac and noncardiac surgery. *Circulation*. 2013;128(25):2785-98.

16. Vicenzi MN, Meisitzer T, Heitzinger B, Halaj M, Fleisher LA, Metzler H. Coronary artery stenting and non-cardiac surgery--a prospective outcome study. *British journal of anaesthesia*. 2006;96(6):686-93.

17. Berger PB, Kleiman NS, Pencina MJ, Hsieh WH, Steinhubl SR, Jeremias A, et al. Frequency of major noncardiac surgery and subsequent adverse events in the year after drug-eluting stent placement results from the EVENT (Evaluation of Drug-Eluting Stents and Ischemic Events) Registry. *JACC Cardiovascular interventions*. 2010;3(9):920-7.

18. Brilakis ES, Cohen DJ, Kleiman NS, Pencina M, Nassif D, Saucedo J, et al. Incidence and clinical outcome of minor surgery in the year after drug-eluting stent implantation: results from the Evaluation of Drug-Eluting Stents and Ischemic Events Registry. *American heart journal*. 2011;161(2):360-6.

19. Cruden NL, Harding SA, Flapan AD, Graham C, Wild SH, Slack R, et al. Previous coronary stent implantation and cardiac events in patients undergoing noncardiac surgery. *Circulation Cardiovascular interventions*. 2010;3(3):236-42.

20. To AC, Armstrong G, Zeng I, Webster MW. Noncardiac surgery and bleeding after percutaneous coronary intervention. *Circulation Cardiovascular interventions*. 2009;2(3):213-21.

21. Fleisher LA, Beckman JA, Brown KA, Calkins H, Chaikof EL, Fleischmann KE, et al. ACC/AHA 2007 guidelines on perioperative cardiovascular evaluation and care for noncardiac surgery: a report of the American College of Cardiology/American Heart Association Task Force on Practice Guidelines (Writing Committee to Revise the 2002 Guidelines on Perioperative Cardiovascular Evaluation for Noncardiac Surgery) developed in collaboration with the American Society of Echocardiography, American Society of Nuclear Cardiology, Heart Rhythm Society, Society of Cardiovascular Anesthesiologists, Society for Cardiovascular Angiography and Interventions, Society for Vascular Medicine and Biology, and Society for Vascular Surgery. *Journal of the American College of Cardiology*. 2007;50(17):e159-241.

22. Chimienti G, Mezzapesa A, Rotelli MT, Lupo L, Pepe G. Plasma concentrations but not serum concentrations of brain-derived neurotrophic factor are related to pro-inflammatory cytokines in patients undergoing major abdominal surgery. *Clinical biochemistry*. 2012;45(9):631-6.

23. Lin MT, Yeh SL, Wu MS, Lin JT, Lee PH, Liaw KY, et al. Impact of surgery on local and systemic responses of cytokines and adhesion molecules. *Hepato-gastroenterology*. 2009;56(94-95):1341-5.
24. Parolari A, Mussoni L, Frigerio M, Naliato M, Alamanni F, Galanti A, et al. Increased prothrombotic state lasting as long as one month after on-pump and off-pump coronary surgery. *The Journal of thoracic and cardiovascular surgery*. 2005;130(2):303-8.
25. Kastrati A, Schomig A, Elezi S, Dirschinger J, Mehilli J, Schuhlen H, et al. Prognostic value of the modified american college of Cardiology/American heart association stenosis morphology classification for long-term angiographic and clinical outcome after coronary stent placement. *Circulation*. 1999;100(12):1285-90.
26. Grines CL, Bonow RO, Casey DE, Jr., Gardner TJ, Lockhart PB, Moliterno DJ, et al. Prevention of premature discontinuation of dual antiplatelet therapy in patients with coronary artery stents: a science advisory from the American Heart Association, American College of Cardiology, Society for Cardiovascular Angiography and Interventions, American College of Surgeons, and American Dental Association, with representation from the American College of Physicians. *Circulation*. 2007;115(6):813-8.
27. Campo G, Fileti L, Valgimigli M, Tebaldi M, Cangiano E, Cavazza C, et al. Poor response to clopidogrel: current and future options for its management. *Journal of thrombosis and thrombolysis*. 2010;30(3):319-31.
28. Sibbing D, Morath T, Braun S, Stegherr J, Mehilli J, Vogt W, et al. Clopidogrel response status assessed with Multiplate point-of-care analysis and the incidence and timing of stent thrombosis over six months following coronary stenting. *Thrombosis and haemostasis*. 2010;103(1):151-9.
29. Sofi F, Marcucci R, Gori AM, Giusti B, Abbate R, Gensini GF. Clopidogrel non-responsiveness and risk of cardiovascular morbidity. An updated meta-analysis. *Thrombosis and haemostasis*. 2010;103(4):841-8.
30. Pfisterer ME, Jeger R, Kaiser CA. Limited usefulness of the modified Academic Research Consortium stent thrombosis definition for clinical trials. *JACC Cardiovascular interventions*. 2011;4(10):1151; author reply -2. Epub 2011/10/25.
31. Luckie M, Khattar RS, Fraser D. Non-cardiac surgery and antiplatelet therapy following coronary artery stenting. *Heart*. 2009;95(16):1303-8.
32. Ferreira-Gonzalez I, Marsal JR, Ribera A, Permanyer-Miralda G, Garcia-Del Blanco B, Marti G, et al. Double antiplatelet therapy after drug-eluting stent implantation: risk associated with discontinuation within the first year. *Journal of the American College of Cardiology*. 2012;60(15):1333-9.
33. Collet JP, Montalescot G, Blanchet B, Tanguy ML, Golmard JL, Choussat R, et al. Impact of prior use or recent withdrawal of oral antiplatelet agents on acute coronary syndromes. *Circulation*. 2004;110(16):2361-7.
34. Kaluza GL, Joseph J, Lee JR, Raizner ME, Raizner AE. Catastrophic outcomes of noncardiac surgery soon after coronary stenting. *Journal of the American College of Cardiology*. 2000;35(5):1288-94.
35. Reddy PR, Vaitkus PT. Risks of noncardiac surgery after coronary stenting. *The American journal of cardiology*. 2005;95(6):755-7.
36. Sharma AK, Ajani AE, Hamwi SM, Maniar P, Lakhani SV, Waksman R, et al. Major noncardiac surgery following coronary stenting: when is it safe to operate? *Catheterization and cardiovascular interventions : official journal of the Society for Cardiac Angiography & Interventions*. 2004;63(2):141-5.
37. Wilson SH, Fasseas P, Orford JL, Lennon RJ, Horlocker T, Charnoff NE, et al. Clinical outcome of patients undergoing non-cardiac surgery in the two months following coronary stenting. *Journal of the American College of Cardiology*. 2003;42(2):234-40.
38. Nasser M, Kapeliovich M, Markiewicz W. Late thrombosis of sirolimus-eluting stents following noncardiac surgery. *Catheterization and cardiovascular interventions : official journal of the Society for Cardiac Angiography & Interventions*. 2005;65(4):516-9.
39. Compton PA, Zankar AA, Adesanya AO, Banerjee S, Brilakis ES. Risk of noncardiac surgery after coronary drug-eluting stent implantation. *The American journal of cardiology*. 2006;98(9):1212-3.
40. Schouten O, van Domburg RT, Bax JJ, de Jaegere PJ, Dunkelgrun M, Feringa HH, et al. Noncardiac surgery after coronary stenting: early surgery and interruption of antiplatelet therapy are associated with an increase in major adverse cardiac events. *Journal of the American College of Cardiology*. 2007;49(1):122-4. Epub 2007/01/09.
41. Gandhi NK, Abdel-Karim AR, Banerjee S, Brilakis ES. Frequency and risk of noncardiac surgery after drug-eluting stent implantation. *Catheterization and cardiovascular interventions : official journal of the Society for Cardiac Angiography & Interventions*. 2011;77(7):972-6.
42. Hawn MT, Graham LA, Richman JS, Itani KM, Henderson WG, Maddox TM. Risk of major adverse cardiac events following noncardiac surgery in patients with coronary stents. *JAMA : the journal of the American Medical Association*. 2013;310(14):1462-72.
43. Mehran R, Baber U, Steg PG, Ariti C, Weisz G, Witzenbichler B, et al. Cessation of dual antiplatelet treatment and cardiac events after percutaneous coronary intervention (PARIS): 2 year results from a prospective observational study. *Lancet*. 2013;382(9906):1714-22.
44. Eisenberg MJ, Richard PR, Libersan D, Filion KB. Safety of short-term discontinuation of antiplatelet therapy in patients with drug-eluting stents. *Circulation*. 2009;119(12):1634-42.
45. Lindblad B, Persson NH, Takolander R, Bergqvist D. Does low-dose acetylsalicylic acid prevent stroke after carotid surgery? A double-blind, placebo-

controlled randomized trial. *Stroke; a journal of cerebral circulation*. 1993;24(8):1125-8.

46. Douketis JD, Spyropoulos AC, Spencer FA, Mayr M, Jaffer AK, Eckman MH, et al. Perioperative management of antithrombotic therapy: Antithrombotic Therapy and Prevention of Thrombosis, 9th ed: American College of Chest Physicians Evidence-Based Clinical Practice Guidelines. *Chest*. 2012;141(2 Suppl):e326S-50S.

47. Chapman TW, Bowley DM, Lambert AW, Walker AJ, Ashley SA, Wilkins DC. Haemorrhage associated with combined clopidogrel and aspirin therapy. *European journal of vascular and endovascular surgery : the official journal of the European Society for Vascular Surgery*. 2001;22(5):478-9.

48. Moore M, Power M. Perioperative hemorrhage and combined clopidogrel and aspirin therapy. *Anesthesiology*. 2004;101(3):792-4.

49. Ernst A, Eberhardt R, Wahidi M, Becker HD, Herth FJ. Effect of routine clopidogrel use on bleeding complications after transbronchial biopsy in humans. *Chest*. 2006;129(3):734-7.

50. Burger W, Chemnitz JM, Kneissl GD, Rucker G. Low-dose aspirin for secondary cardiovascular prevention - cardiovascular risks after its perioperative withdrawal versus bleeding risks with its continuation - review and meta-analysis. *Journal of internal medicine*. 2005;257(5):399-414.

51. Korte W, Cattaneo M, Chassot PG, Eichinger S, von Heymann C, Hofmann N, et al. Peri-operative management of antiplatelet therapy in patients with coronary artery disease: joint position paper by members of the working group on Perioperative Haemostasis of the Society on Thrombosis and Haemostasis Research (GTH), the working group on Perioperative Coagulation of the Austrian Society for Anesthesiology, Resuscitation and Intensive Care (OGARI) and the Working Group Thrombosis of the European Society for Cardiology (ESC). *Thrombosis and haemostasis*. 2011;105(5):743-9.

52. Angiolillo DJ, Capranzano P. Pharmacology of emerging novel platelet inhibitors. *American heart journal*. 2008;156(2 Suppl):S10-5.

53. Wiviott SD, Braunwald E, McCabe CH, Montalescot G, Ruzyllo W, Gottlieb S, et al. Prasugrel versus clopidogrel in patients with acute coronary syndromes. *The New England journal of medicine*. 2007;357(20):2001-15.

54. Held C, Asenblad N, Bassand JP, Becker RC, Cannon CP, Claeys MJ, et al. Ticagrelor versus clopidogrel in patients with acute coronary syndromes undergoing coronary artery bypass surgery: results from the PLATO (Platelet Inhibition and Patient Outcomes) trial. *Journal of the American College of Cardiology*. 2011;57(6):672-84.

55. Wijns W, Kolh P, Danchin N, Di Mario C, Falk V, Folliguet T, et al. Guidelines on myocardial revascularization. *European heart journal*. 2010;31(20):2501-55.

56. Karkouti K, McCluskey SA, Syed S, Pazaratz C, Poonawala H, Crowther MA. The influence of perioperative coagulation status on postoperative blood loss in complex cardiac surgery: a prospective observational study. *Anesthesia and analgesia*. 2010;110(6):1533-40. Epub 2010/05/04.

57. Sim DS, Merrill-Skoloff G, Furie BC, Furie B, Flaumenhaft R. Initial accumulation of platelets during arterial thrombus formation in vivo is inhibited by elevation of basal cAMP levels. *Blood*. 2004;103(6):2127-34.

58. Wilczynski M, Bochenek T, Goral J, Knast K, Abu Samra R, Wita K, et al. [Use of eptifibatid in patients with acute stent thrombosis, requiring urgent surgical revascularisation - report of 2 cases]. *Kardiologia polska*. 2009;67(11):1313-6.

59. Savonitto S, D'Urbano M, Caracciolo M, Barlocco F, Mariani G, Nichelatti M, et al. Urgent surgery in patients with a recently implanted coronary drug-eluting stent: a phase II study of 'bridging' antiplatelet therapy with tirofiban during temporary withdrawal of clopidogrel. *British journal of anaesthesia*. 2010;104(3):285-91.

60. Faulds D, Sorkin EM. Abciximab (c7E3 Fab). A review of its pharmacology and therapeutic potential in ischaemic heart disease. *Drugs*. 1994;48(4):583-98.

61. Angiolillo DJ, Firstenberg MS, Price MJ, Tummala PE, Hutyra M, Welsby IJ, et al. Bridging antiplatelet therapy with cangrelor in patients undergoing cardiac surgery: a randomized controlled trial. *JAMA : the journal of the American Medical Association*. 2012;307(3):265-74.

62. Joner M, Finn AV, Farb A, Mont EK, Kolodgie FD, Ladich E, et al. Pathology of drug-eluting stents in humans: delayed healing and late thrombotic risk. *Journal of the American College of Cardiology*. 2006;48(1):193-202.

63. Nebeker JR, Virmani R, Bennett CL, Hoffman JM, Samore MH, Alvarez J, et al. Hypersensitivity cases associated with drug-eluting coronary stents: a review of available cases from the Research on Adverse Drug Events and Reports (RADAR) project. *Journal of the American College of Cardiology*. 2006;47(1):175-81.

64. Virmani R, Guagliumi G, Farb A, Musumeci G, Grieco N, Motta T, et al. Localized hypersensitivity and late coronary thrombosis secondary to a sirolimus-eluting stent: should we be cautious? *Circulation*. 2004;109(6):701-5.

65. Gwon HC, Hahn JY, Park KW, Song YB, Chae IH, Lim DS, et al. Six-month versus 12-month dual antiplatelet therapy after implantation of drug-eluting stents: the Efficacy of Xience/Promus Versus Cypher to Reduce Late Loss After Stenting (EXCELLENT) randomized, multicenter study. *Circulation*. 2012;125(3):505-13.

66. Kim BK, Hong MK, Shin DH, Nam CM, Kim JS, Ko YG, et al. A new strategy for discontinuation of dual antiplatelet therapy: the RESET Trial (REal Safety

- and Efficacy of 3-month dual antiplatelet Therapy following Endeavor zotarolimus-eluting stent implantation). *Journal of the American College of Cardiology*. 2012;60(15):1340-8.
67. Abizaid A, Costa JR, Jr. New drug-eluting stents: an overview on biodegradable and polymer-free next-generation stent systems. *Circulation Cardiovascular interventions*. 2010;3(4):384-93.
68. Paccagnella A, Majni G, Ottaviani G, Arru P, Santi M, Vallana F. Properties of a new carbon film for biomedical applications. *The International journal of artificial organs*. 1986;9(2):127-30.
69. Bartorelli AL, Trabattoni D, Fabbiochi F, Montorsi P, de Martini S, Calligaris G, et al. Synergy of passive coating and targeted drug delivery: the tacrolimus-eluting Janus CarboStent. *Journal of interventional cardiology*. 2003;16(6):499-505.
70. Morice MC, Bestehorn HP, Carrie D, Macaya C, Aengevaeren W, Wijns W, et al. Direct stenting of de novo coronary stenoses with tacrolimus-eluting versus carbon-coated carbostents. The randomized JUPITER II trial. *EuroIntervention : journal of EuroPCR in collaboration with the Working Group on Interventional Cardiology of the European Society of Cardiology*. 2006;2(1):45-52.
71. Cassese S, De Luca G, Villari B, Berti S, Bellone P, Alfieri A, et al. Reduced antiplatelet therapy after drug-eluting stenting: multicenter Janus Flex carbostent implantation with short dual antiplatelet treatment for 2 or 6 months-MATRIX study. *Catheterization and cardiovascular interventions : official journal of the Society for Cardiac Angiography & Interventions*. 2012;80(3):408-16.
72. Aoki J, Serruys PW, van Beusekom H, Ong AT, McFadden EP, Sianos G, et al. Endothelial progenitor cell capture by stents coated with antibody against CD34: the HEALING-FIM (Healthy Endothelial Accelerated Lining Inhibits Neointimal Growth-First In Man) Registry. *Journal of the American College of Cardiology*. 2005;45(10):1574-9.
73. Duckers HJ, Soullie T, den Heijer P, Rensing B, de Winter RJ, Rau M, et al. Accelerated vascular repair following percutaneous coronary intervention by capture of endothelial progenitor cells promotes regression of neointimal growth at long term follow-up: final results of the Healing II trial using an endothelial progenitor cell capturing stent (Genous R stent). *EuroIntervention : journal of EuroPCR in collaboration with the Working Group on Interventional Cardiology of the European Society of Cardiology*. 2007;3(3):350-8.
74. Werner N, Junk S, Laufs U, Link A, Walenta K, Bohm M, et al. Intravenous transfusion of endothelial progenitor cells reduces neointima formation after vascular injury. *Circulation research*. 2003;93(2):e17-24.
75. Piscione F, Cassese S, Galasso G, Cirillo P, Esposito G, Rapacciuolo A, et al. A new approach to percutaneous coronary revascularization in patients requiring undeferrable non-cardiac surgery. *International journal of cardiology*. 2011;146(3):399-403.
76. Cassese S, Galasso G, Sciahbasi A, Scacciatella P, Mujaj A, Piccolo R, et al. Antiplatelet therapy after Genous EPC-capturing coronary stent implantation: The ARGENTO Study: a prospective, multicenter registry. *International journal of cardiology*. 2013;167(3):757-61.