

UNIVERSITÀ DEGLI STUDI DI SALERNO



Dipartimento di Medicina e Chirurgia

Corso di Dottorato in Medicina Traslazionale e Clinica

XIV Ciclo

TESI DI DOTTORATO

***Essential Infantile Esotropia with Inferior Oblique
hyperfunction and Lateral Recti pseudoparalysis:
long term follow-up of 6 muscles approach***

Coordinatore
Ch.ma Prof. Amelia Filippelli

A handwritten signature in black ink, appearing to read "A. Filippelli", is written below the name of the coordinator.

Candidata
Roberta Carelli

Tutor
Ch.mo Prof. Adriano Magli

Anno Accademico 2015/2016

INDEX

INTRODUCTION	5
MATERIALS AND METHODS.....	14
RESULTS.....	19
DISCUSSION.....	37
<i>Non-Surgical Interventions - Use of Botulinum Toxin</i>	37
<i>Age at intervention</i>	39
<i>Surgical techniques</i>	42
CONCLUSION	53
REFERENCES.....	55

INTRODUCTION

Infantile esotropia (IE) is a constant stable angle esotropia with an onset within the first six months of life¹.

The reported incidence of infantile esotropia varies between 0.1% and 1%²⁻⁶

Features associated with IE include:

- constant angle >30 PD
- excessive adduction
- cross-fixation
- abduction restriction
- latent nystagmus or manifest-latent nystagmus (oscillation of the eyes, which increases when either eye is covered)
- asymmetry of optokinetic nystagmus; a following movement followed by a rapid fixation movement in the opposite direction. This can be demonstrated by using a rotating, striped drum
- over-acting inferior oblique muscles. This usually occurs bilaterally but can be asymmetrical, leading to the development of a hypertropia in one or more positions of gaze (most prominent in adduction)
- dissociated vertical deviation (DVD); either eye elevates resulting in a hypertropia when the amount of light entering it is reduced⁷. This can also occur during a period of inattention or fatigue and can contribute to the hypertropia in adduction, since the nose can act as an occluder to the image being viewed
- refractive error within normal limits < 3 D; low hypermetropia after complete cycloplegic refraction
- medium grade amblyopia
- suppression, resulting in absence of binocular single vision (BSV)
- no neurological abnormalities

Ophthalmological and orthoptic examinations are carried out mainly in order to diagnose or rule out the presence of amblyopia, establish strabismus type, evaluate and define deviation angle, analyze sensory state (for unilateral or alternating exclusion, central suppression, anomalous retinal correspondence, binocular single vision) and stereopsis.

Without doubt, IE therapy is focused on surgery, however surgical intervention is subordinate to several conditions: horizontal deviation stability, estimation of vertical deviation (if any), absence of accommodative factors, presence of alternating fixation (spontaneous or re-educated), sufficient patient cooperation to set up an appropriate operative program. Surgery is usually performed on horizontal recti, adding oblique muscles if needed.

Different studies assess the effectiveness of various surgical and non-surgical interventions for IE and try to determine the ideal age at treatment.

Treatment options

Treatment aims to improve ocular misalignment. However, another important issue to consider is whether such treatment facilitates and enhances the development of binocular vision (BSV).

Therefore there are two aims of intervention:

1. align the visual axes
2. optimize the potential for binocularity

Previously, many authorities believed that alignment within 10 diopters of orthotropia by two years of age offers the best prospect for the development of binocular vision⁸.

Primary outcomes

1. Improvement in the angle of the squint. Angle at near (and distance if possible) is measured by prism cover test, Kimsky or synoptophore. An angle within 10 pD (+/-) of orthotropia at long term follow-up is considered a successful outcome.
2. Presence and quality of binocularity. A wide range of tests exist to diagnose the presence and the quality of binocular vision, with a measurement of stereoacuity considered the 'gold standard'.

Secondary outcomes

1. Over-correction
2. Under-correction
3. Number of interventions required

Although previous studies have compared treatment strategies, there are currently no clinical guidelines to determine the most effective age or treatment for IE.

The age at which surgery is performed can vary and authors have used various terms to describe the timing of surgery. For example, 'ultra-early' has been used to describe surgical intervention between four and six months⁹, 'early' to describe surgery before the age of two, and 'late' to describe surgery after the age of two.

Non-surgical treatment

The main form of non-surgical management in IE is botulinum toxin (BT). This drug comes from a bacterium called *Clostridium botulinum*, which produces toxins that can be used to block muscle contractions. The most commonly used toxin type for injection into muscles is botulinum toxin A¹⁰. The toxin is injected into the medial recti to temporarily paralyze the muscles and weaken their action, allowing the antagonist muscles (the lateral recti) to act unopposed. When the paralytic effect wears off, after several months, the alignment may be improved.

Surgical treatment

The standard forms of surgical intervention are variable and include: bilateral MR recession, unilateral rec/res, bilateral MR recession with unilateral LR resection, bilateral MR rec/ LR res¹¹.

In cases of small deviation angles, the traditional surgical approach, is medial recti bilateral recession associated if needed, with lateral recti resection. Although it has been shown that bilateral MR recession greater than 5 mm are an acceptable treatment, many surgeons still opt for three to four muscle surgery for IE treatment¹²⁻¹⁵. In fact, surgery can be performed on 3 muscles, with double medial recti recession and

unilateral lateral rectus resection or on 4 muscles (double medial recti recession with bilateral resection of the lateral recti).

Nevertheless, optimal surgical technique is still controversial.

Surgical adjustment of the vertically acting muscles may also be undertaken to correct any significant hypertropia, such as weakening of the inferior oblique muscle in cases with IO hyperfunction.

Inferior oblique treatment

Over the past years, the management of inferior oblique overaction has improved substantially. Historically, inferior oblique surgery was considered extremely difficult and fraught with complications, such as fat adherence, ciliary nerve damage with pupillary dilatation, and intraoperative hemorrhage.

Selection of the appropriate surgical procedure is based on the amount of inferior oblique dysfunction. Inferior oblique overaction is clinically estimated on a scale of +1 through +4.

When performing versions to test for inferior oblique overaction, make sure the abducting eye is fixing, so the adducting fellow eye is free to manifest an “upshoot.”. Quantify the upshoot by bringing the fixing eye straight across to the lateral canthus, and observe the adducting eye for upshoot (Figure 1).

Inferior oblique overaction can cause a V pattern-Y subtype with most of the divergence occurring from primary position to up-gaze. The final quantification of inferior oblique overaction should be based on the combined characteristics of the upshoot degree and on the amount of V pattern.

According to Wright, patients with +2 or more IO overaction are candidates for an inferior oblique surgery, while those with +1 or less can usually be followed.

Patients with slight inferior oblique overaction, but a significant V pattern (> 15 PD), are exceptions to this rule; these patients should be considered for IO weakening even though versions show a minimal inferior oblique overaction.

Primary inferior oblique overaction is usually bilateral and almost always requires bilateral surgery. In cases of asymmetric overaction, bilateral surgery should be

performed, even when one eye displays only +1 overaction, to avoid unmasking the minimal overaction.

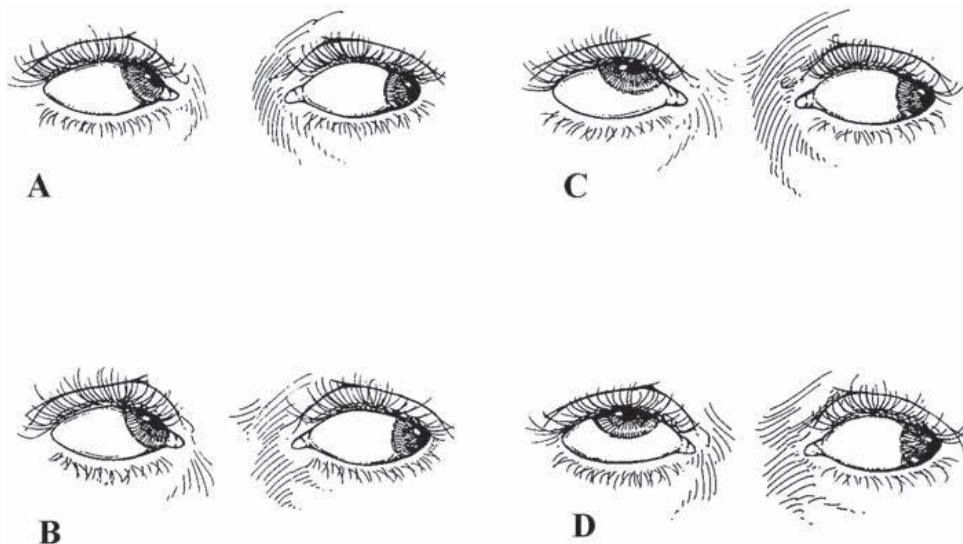


Fig 1. Quantification of upshoot in inferior oblique overaction.

(A) Minimal upshoot (+1) of adducting eye when taken straight across. Upshoot is better seen when the abducting eye is moved up and out.

(B) Upshoot (+2) of adducting eye is obvious when the abducting eye looks straight across at the lateral canthus.

(C) Severe upshoot (+3) of adducting eye is seen even with abducting eye in straight abduction.

(D) Very severe upshoot (+4) of adducting eye is seen as the fixing eye moves straight across into abduction. In addition to a severe upshoot, there will be an abduction movement as the adducting eye is elevated into the field of action of the inferior oblique.

The classification we have used in the current work (ranging from + to +++) was slightly different from “Wright’s” tables, defining surgical indication even in cases with 1+.

If a significant amblyopia is present, according to some authors, it may seem safer to restrict surgery to the amblyopic eye. In these cases, unilateral surgery is sufficient because the sound eye is always fixing and will not manifest an upshoot.

Surgical management of IO muscle overaction is based on weakening or changing the function of the inferior oblique muscle.

An inferior oblique recession acts by inducing muscle slack, thus reducing muscle tension. This is accomplished by moving the muscle insertion closer to the origin, up along the arc of contact of the muscle. Fink described an 8 mm recession site and Apt subsequently found this site by measuring a point 4 mm posterior and 4.4 mm superior to the inferior rectus insertion. Parks suggested placing the muscle close to the vortex vein for moderate IO overaction.

In our work, a bilateral inferior oblique recession with anteroposition was performed. After recession, IO was sutured between lateral rectus and inferior rectus, at the equator. The greater IO hyperfunction, the closer IO was sutured near inferior rectus muscle.

On the other hand a newer procedure, the anteriorization procedure has improved outcomes, especially for the treatment of severe inferior oblique overaction.

The anteriorization procedure changes the vector of forces by moving the inferior oblique muscle insertion anterior towards the inferior rectus insertion (Figure 2). This changes the inferior oblique from an elevator to more of a depressor.

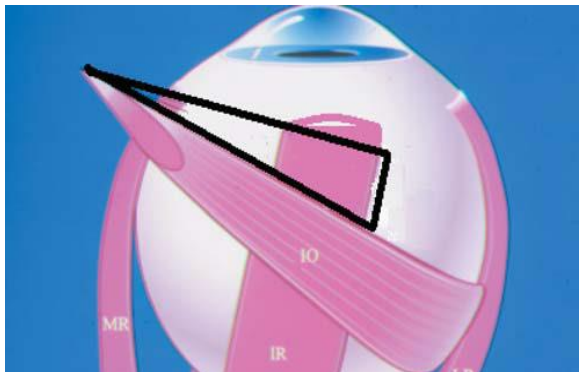


Fig 2

Anteriorization of the inferior oblique muscle consists of moving the insertion to the temporal border of the inferior rectus muscle close to the inferior rectus insertion.

Note the anteriorization is shown in black and the new insertion is parallel to the inferior rectus muscle.

Furthermore, the so called “graded anteriorization” procedure is Wright’s procedure of choice for mild to severe IO overaction. The basis of the graded anteriorization procedure is that the more anterior the inferior oblique insertion, the greater the weakening effect. This procedure tailors the amount of anteriorization to the amount of IO overaction.

In the 1980s, Wright developed a “new” modification of the anteriorization procedure based on keeping the posterior fibers behind the inferior rectus insertion, to prevent limitation of elevation, and a graded anterior placement of the muscle depending on the severity of the inferior oblique overaction. Results of the graded anteriorization have been excellent, in Wright’s experience, with over 90% success rate for mild to severe inferior oblique overaction.

Figure 3 shows the “Graded Anteriorization” developed by Wright and the inferior oblique placement for a specific amount of inferior oblique overaction.

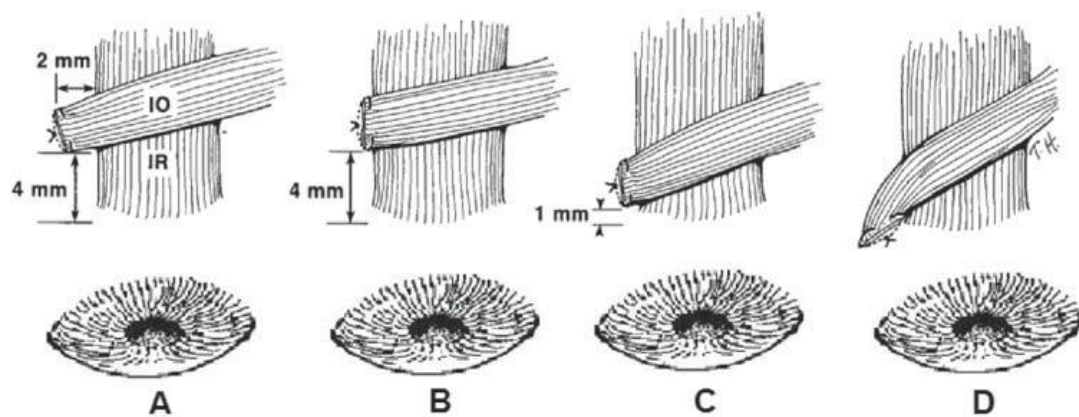


Fig 3. The more anterior the new insertion the greater the weakening effect.

(A) This figure shows the least amount of anteriorization for IO overaction.

(B) The muscle is placed 4 mm posterior to the inferior rectus insertion for moderate overaction.

(C) The anteriorization procedure for severe overaction is shown.

(D) Anteriorization of the entire IO insertion, including the posterior fibers. Anteriorization of the posterior fibers creates a “J” deformity and limits elevation of the eye.

In “J anteriorization”, with placement of the posterior fibers at, or anterior to, the inferior rectus insertion produces a “J” deformity, and will limit elevation of the eye. The “J” deformity anteriorization is associated with limited elevation so it is rarely used, except if performed bilaterally for severe inferior oblique overaction and DVD (Figure 3 D). The complication of limited elevation has been termed by Mims as anti-elevation syndrome. Stager has shown, through anatomical dissections, that the neurofibrovascular bundle of the inferior oblique inserts into the posterior fibers and

can act as a tether to hold the eye down. He found that the ligamentous structure of the neurofibrovascular bundle provides the ancillary origin for the posterior temporal fibers of the inferior oblique muscle when its insertion is transposed anteriorly. Because of these concerns, the full anteriorization with a “J” deformity should be reserved for severe bilateral DVD with inferior oblique overaction. Mims stated that the author’s procedure of keeping the posterior fibers posterior to the inferior rectus insertion prevents this complication.

Although the above figures provide guidelines for managing IO overaction, the final surgical decision must be based on a combination of factors, including the amount of V pattern and the presence of a vertical deviation in primary position.

If inferior oblique overaction is associated with horizontal strabismus, surgery for inferior oblique dysfunction should be performed along with the horizontal strabismus surgery. Recent data suggest that weakening the inferior oblique muscle will not significantly alter the horizontal alignment in primary position.

When planning simultaneous horizontal and inferior oblique surgery, the amount of horizontal surgery should be based on the measurement in primary position, independent of the IO surgery.

In IE treatment, the adverse effects may be effects from surgery (such as conjunctival scarring, inflammation, rare anterior segment ischaemia etc) or from botulinum toxin injections (for example spread of toxin to nearby muscles causing ptosis) and development of amblyopia. These can be classified as major (requiring further intervention) and minor (requiring no further intervention) ¹⁶.

As previously described, in children presenting IE associated with IO hyperfunction and a degree of LR pseudoparalysis, it is also possible to perform a 6 muscles approach in a single surgical session, including medial recti, lateral recti and inferior oblique muscles. In our cohort, IO procedure was performed as following: IO recession + anteriorization with IO suture between lateral rectus and inferior oblique, at the equator.

The aim of our study is the analysis of long-term follow-up (10 years) in IE, after a 6 muscles surgical approach, with bilateral MR recession, bilateral LR resection and bilateral IO recession and anteriorization.

MATERIALS AND METHODS

A retrospective assessment was performed. Data were retrospectively collected in 2014-2015.

Setting of the study are the Ophthalmology Department of a Teaching Hospital (University of Salerno), the Pediatric Ophthalmology Department (Naples University) and a Private practice (Italy).

Surgeries were performed between 2002 and 2005.

Informed consent was obtained, in agreement with the declaration of Helsinki.

213 patients were initially included (103 F, 110 M). Tab 1 shows all inclusion criteria.

Inclusion Criteria

Confirmed IE diagnosis

Strabismus Angle ≥ 30 PD

Angle Stability

Absence of associated ocular anomalies

Absence of CNS anomalies

IE onset by the first 6 months of age

Preoperative hypermetropia < 3 D

No previous extraocular muscle surgery

Surgery performed ≤ 4 years of age

IO hyperfunction

Tab 1.

Exclusion criteria are angle variability, reoperations and uncomplete follow-up.

Patients presenting angle variability were excluded. Deviation variability was defined when the horizontal deviation angle showed a difference ≥ 15 PD between the first, second and third pre-operative visit. Variability may be due to lack of cooperation during examination, the angle was not yet stable or a minimal AC/A ratio abnormality may be found during follow-up. These children, due to a relevant angle difference during preoperative examinations, were more likely to represent a bias for our results; for this reason they were excluded from our study.

Final cohort included 108 children. All patients were showing a preoperative angle ≥ 30 PD, angle Stability, IE onset before 6 months of age, IO hyperfunction, surgery performed ≤ 4 years of age, hyperopia < 3 D.

Preoperative assessment and complete orthoptic and clinical evaluation were performed pre-operatively. Between one and three detailed examinations were carried out before surgery, in order to establish angle stability, define clinical data and sensory state. All smaller children had undergone more than one examination in order to better quantify the strabismus angle, the IO hyperfunction, the LR pseudoparalysis and, if present, the vertical deviation.

Familiarity for strabismus (positivity if strabismus, not necessarily IE, was present in the family) and systemic conditions were recorded.

All patients underwent a complete orthoptic and clinical examination.

- Esotropia type (RE or LE prevalence; alternating esotropia)
- Horizontal angle deviation was estimated after refractive error total correction. Angle stability was assessed. Mean deviation between near and distance was measured by Krimsky test; cover-test was used in cooperative patients
- Deviation variability (variability was defined when the horizontal deviation angle showed a difference ≥ 15 pD between the first, second and third pre-operative

visit; patients presenting variability were excluded from the statistical data analysis)

- Antiamblyopic occlusion treatment (prevalently on RE, LE or alternating RE-LE patching)
- Ductions and versions, including Inferior Oblique (IO), Superior Oblique (SO), Lateral Rectus (LR), Superior Rectus (SR) and Inferior Rectus (IR) muscles hyper/hypo functions
- LR Pseudoparalysis. Bilateral LR Pseudoparalysis was defined as abduction deficit recordable only during versions examination, movement is WNL in ductions. Bilateral LR abduction limitation was considered as incomplete movement also by examining ductions
- Alphabetical variations (V or A) were reported, if present
- Up-shoot was set-up in all patients, using an arbitrary scale from (+) to (++++), where the greatest number of + indicated the greatest up-shoot; both RE and LE up-shoots were reported, thus bringing to light any differences between the two eyes (different classification from “Wright’s” tables)
- DVD
- Abnormal head position (AHP)
- Cross-fixation
- Nystagmus
- Visual Acuity (UCVA and BCVA) and Amblyopia assessment. Classification of amblyopia degree is variable among different authors. We consider mild amblyopia as a BCVA greater than 0.2 logMAR, medium grade or moderate amblyopia a BCVA between 0.2 and 0.5 logMAR, severe amblyopia a BCVA lower than 0.5 logMAR
- Hypermetropia; cycloplegic refraction was performed to rule out refractive errors
- Spherical equivalent was evaluated during follow-up at last examination
- Sensory state evaluation ; presence of exclusion (unilateral or alternating exclusion) and Binocular Single Vision (BSV) with different stereopsis degrees were reported

- Anterior chamber, gonioscopy and Fundus oculi were examined, evaluating the presence of dioptric means abnormalities and assessing a differential diagnosis.

All patients underwent a 6 muscles approach surgery, under general anesthesia, within the first 4 years of life.

All patients were operated on by a single surgeon (A.M.) and were followed up by the same orthoptic team.

All patients underwent:

- bilateral medial recti recession (limbal incision with direct scleral fixation)
- bilateral lateral recti resection (limbal incision with direct scleral fixation)
- bilateral inferior oblique recession with anteroposition: IO recession + anteriorization with IO suture between lateral rectus and inferior rectus, at the equator. The greater IO hyperfunction, the closer IO was sutured near inferior rectus muscle.

Informed consent was obtained prior to surgery from the parents, after complete information concerning peri-operative and post-operative risks. All surgical procedures were conducted in accordance with the guidelines of the Declaration of Helsinki.

All patients were discharged the day after surgery. Patients were treated with steroid-antibiotic topical eye drops, 3 times a day, for 20 days following operation and systemic antibiotics for 5 days after surgery.

Follow-up was performed after surgery: 3 months, 2 years, 5 years, 10 years. Complete clinical and orthoptic parameters were estimated postoperatively.

Statistical analysis

A two-tailed paired t-test was performed to compare baseline distance and near deviation and those at 3 months, 2, 5 and 10 years after surgery. Pearson's correlation was also applied in order to examine a possible relationship between the muscles' recession/resection and the residual deviation and the relationship between residual deviation and refractive error.

For all analyses, a conservative p-value of < 0.05 was considered as statistically significant.

SAS statistical software package (version 9.1, SAS Institute Inc, Cary, NC) was used.

RESULTS

All patients underwent a 6 muscles approach: bilateral MR recession (4-5 mm), bilateral LR resection (< 7 mm), bilateral IO recession and anteriorization.

All patients were operated on between 20 months and 4 years of age. Mean age at operation was $2,86 \pm 0,83$ (Mean \pm sd), median 3, range [2; 4]

Post-operative success was defined by the following deviation criteria:

- orthotropic (0 PD)
- small angle residual ET (0 to +10 pD)
- small angle secondary XT (0 to -10 pD)
- ET (> + 10 pD)
- XT (angle greater than -10 pD)

Absence of abduction limitation/ LR pseudoparalysis was reported in 9 patients , bilateral LR Pseudoparalysis in 36 patients , while bilateral LR abduction limitation in 63 patients

Upshoot was recorded in all 108 patients. It was defined as + in 66 patients , ++ in 33 patients (of whom 3 RE > LE and 24 LE > RE), and +++ in 9 patients (different classification from "Wright's" tables).

Mean surgical approach, In terms of mm is reported in Table 2.

Tab 2.

	RE				LE			
	MR rec	conj rec	LR res	IO rec	MR rec	conj rec	LR res	IO rec
mean	4,51±	4,13±	6,59±	6,34±	4,52±	4,16±	6,83±	6,89±
mm ± sd	0,57	0,71	0,69	1,11	0,51	0,79	0,65	1,11
Range [min; max]	[3; 6]	[4; 8]	[4; 8]	[4; 8]	[4; 5,5]	[4; 8]	[5; 8]	[5; 9]
median	3	4	7	7,5	4,5	4	7	7

Deviation during follow-up is expressed in Table 3.

Tab 3 Deviation during follow-up.

Follow-up		Ocular alignment (pD)				
		> -10 ^Δ	from -1 ^Δ to -10 ^Δ	0	from +1 ^Δ to +10 ^Δ	> +10 ^Δ
3 months	n (%)	27 (25,0)	12 (11,1)	24 (22,2)	24 (22,2)	21 (19,4)
2 years	n (%)	12 (11,1)	24 (22,2)	18 (16,7)	24 (22,2)	30 (27,8)
5 years	n (%)	9 (8,3)	24 (22,2)	27 (25)	24 (22,2)	24 (22,2)
10 years	n (%)	12 (11,1)	24 (22,2)	30 (27,8)	27 (25,0)	15 (13,9)

During all follow-up, except for 3 months after surgery, we report a higher incidence of residual ET compared to secondary XT. This result supports our hypothesis; a multiple muscles procedure doesn't necessary leads to an hypercorrection.

At 10 years postoperative follow-up, incidence of secondary XT together with incidence of residual ET is 25 % (11,1 % + 13,9 %). Of these, 12 patients were presenting ET greater than + 15 PD and 9 patients showed XT > -18.

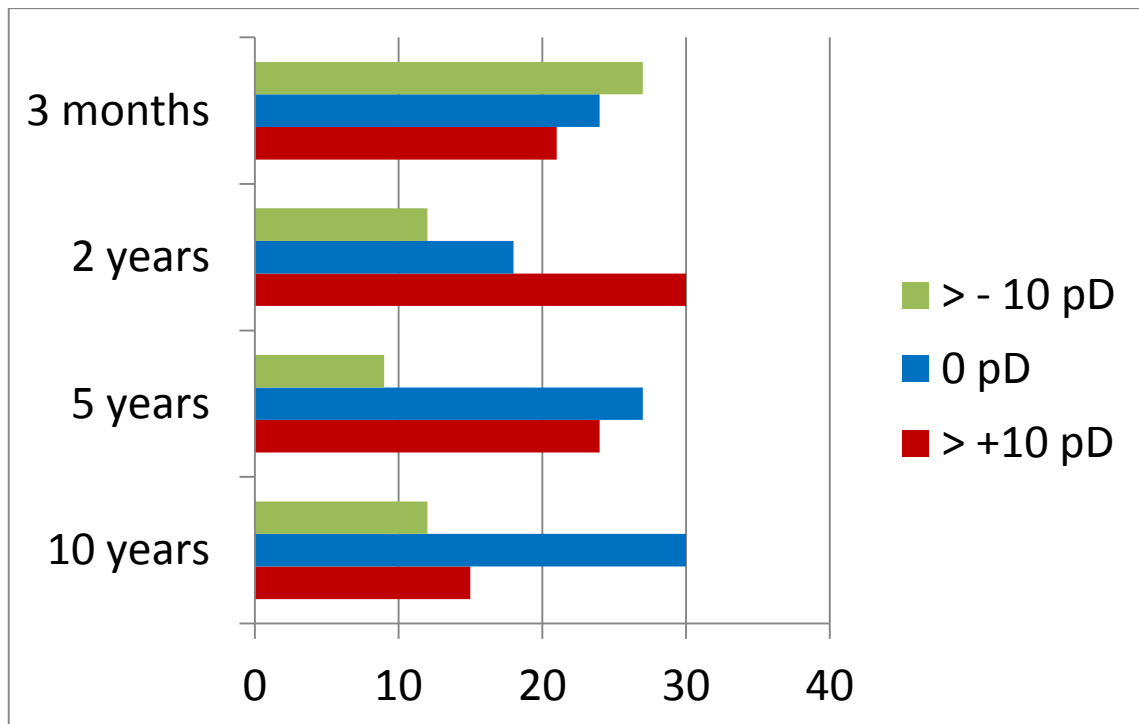


Fig 4. Postoperative deviation during follow-up

Figure 4 shows postoperative deviation during follow-up 3 months, 2 years, 5 years, 10 years, concerning residual ET, secondary XT and orthotropia.

Postoperative XT 3 months after surgery shows a reduction during follow-up.

On the other hand, postoperative ET increased 2 years after surgery and reduced afterwards.

Considering all sample (n=108), data report a slight, significant, increase of deviation 2 years after surgery, compared to follow-up performed 3 months after surgery ($p < 0.01$)

A stability of results is reported during time, with a trend of mean residual deviation reduction ($p=0.04$).

According to the two examined groups, Table 4 and Fig 5 express deviation follow-up in the two groups. showing a similar pattern during follow-up.

Tab 4 Deviation in the two different groups

		Before surgery	Follow-up after surgery			
			3 months	2 years	5 years	10 years
$\leq 40^{\Delta}$	mean horizontal deviation \pm sd	37,50 \pm 4,2	-1,17 \pm 13,83	2,22 \pm 10,68	1,67 \pm 10,41	0,22 \pm 11,67
	range [min; max]	[30; +40]	[-20; 30]	[-14; 30]	[-20; 20]	[-20; 30]
	median	40	-2	0	0	0
$> 40^{\Delta}$	mean horizontal deviation \pm sd	51,94 \pm 5,61	1,33 \pm 12,35	4,89 \pm 13,12	3,89 \pm 12,30	2,17 \pm 10,32
	range [min; max]	[45; 60]	[-25; 25]	[-14; 30]	[-20; 20]	[-20; 18]
	median	50	2	6	8	0

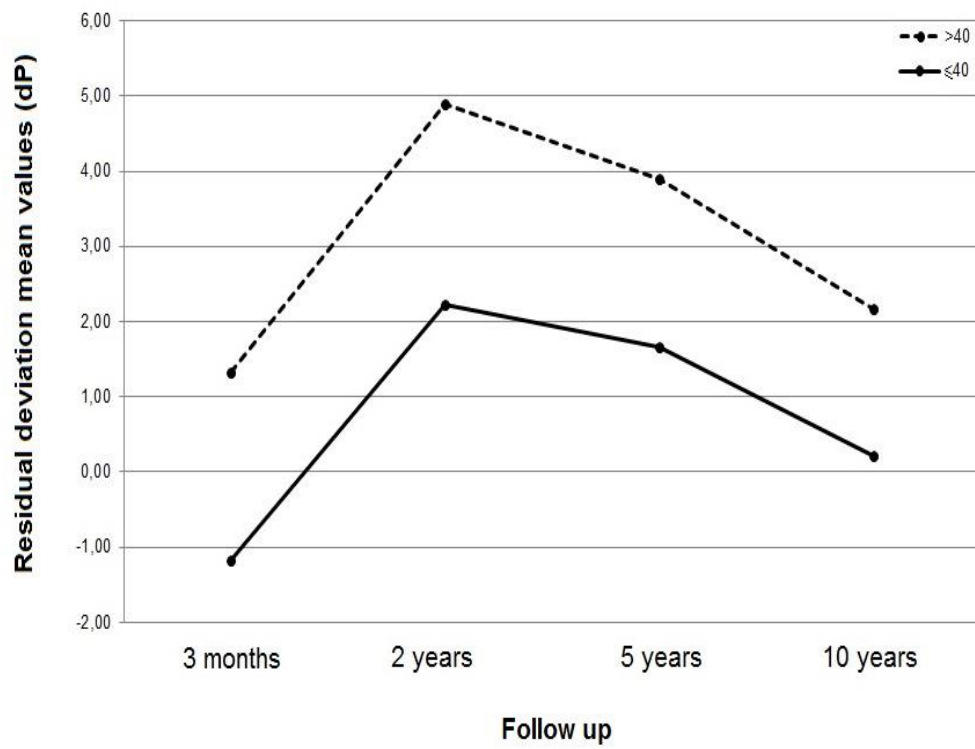
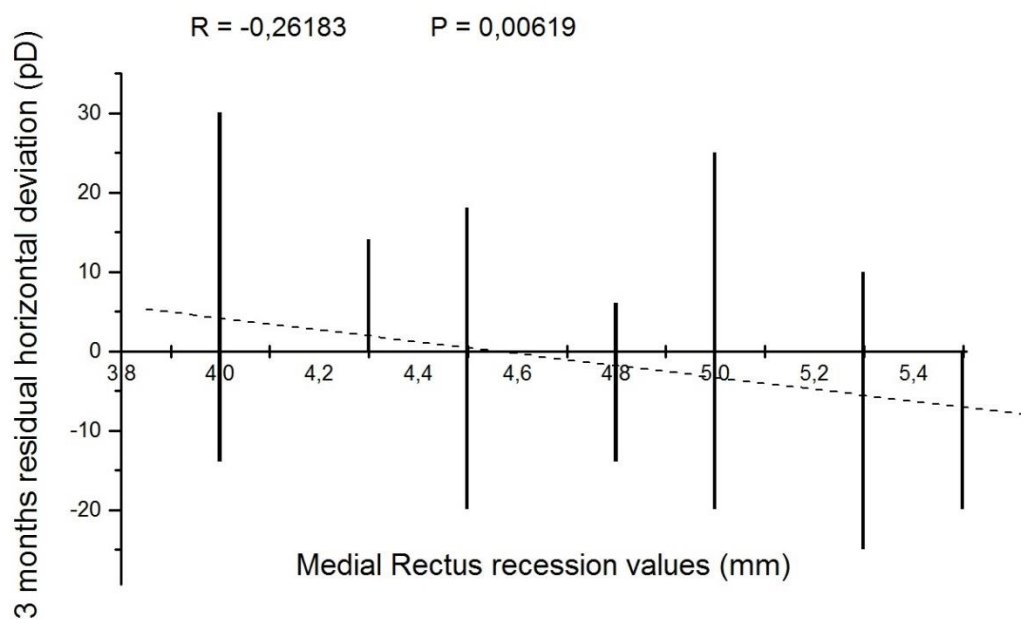


Fig 5 Horizontal deviation during follow-up in the two examined groups

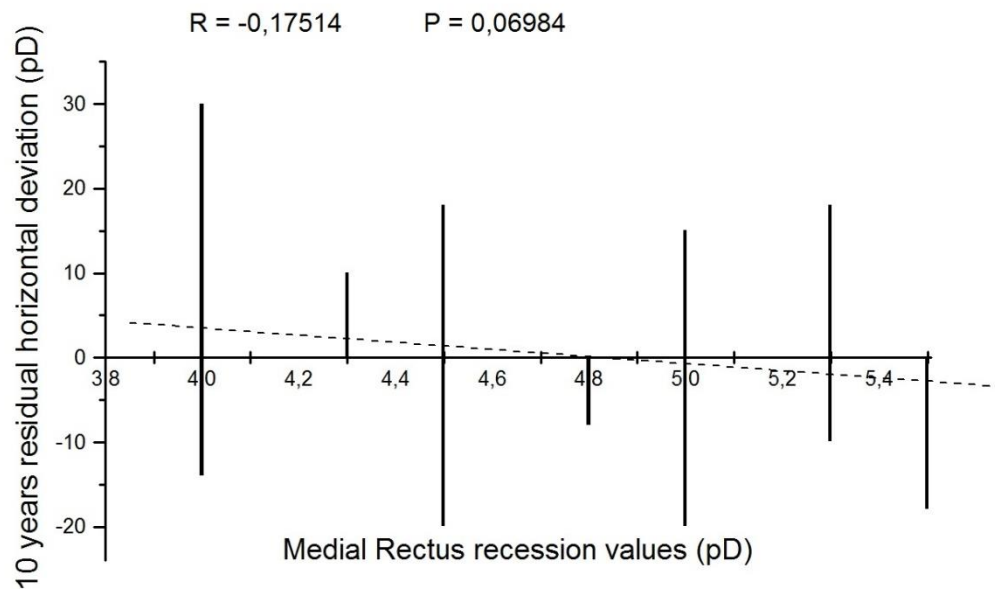
Correlations among MR recession, LR resection and IO recession were analyzed and reported in Fig 6 (A-B), Fig 7 (A-B) and Fig 8 (A-B).

Fig 6A Correlation between MR recession (mm) and 3 months horizontal residual deviation (PD)



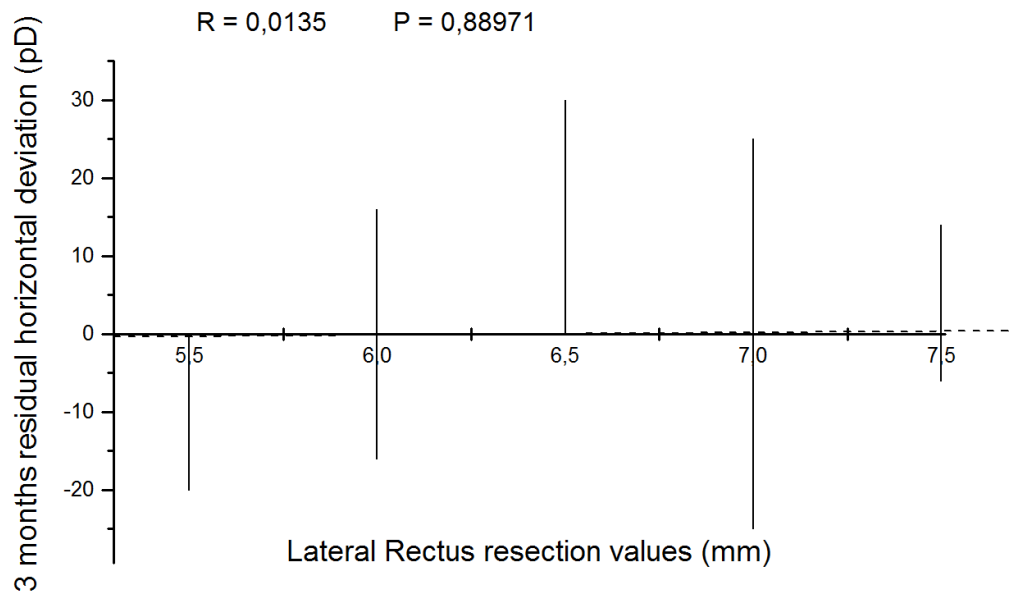
Results show a significant correlation between mean MR recession entity (in both eyes) and postoperative deviation at 3 months follow-up ($p < 0.05$)

Fig 6B Correlation between MR recession (mm) and 10 years horizontal residual deviation (PD)



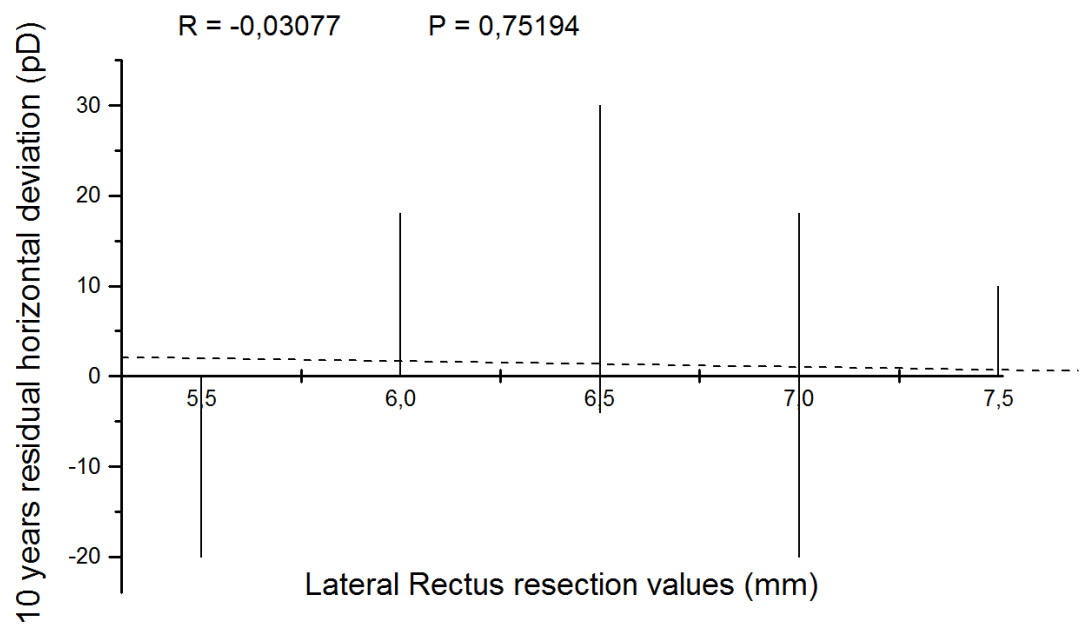
No significant correlations between MR recession entity and 10 years postoperative horizontal deviation was reported. Nevertheless, a trend of significance is to be mentioned.

Fig 7A Correlation between LR resection (mm) and 3 months horizontal residual deviation (PD)



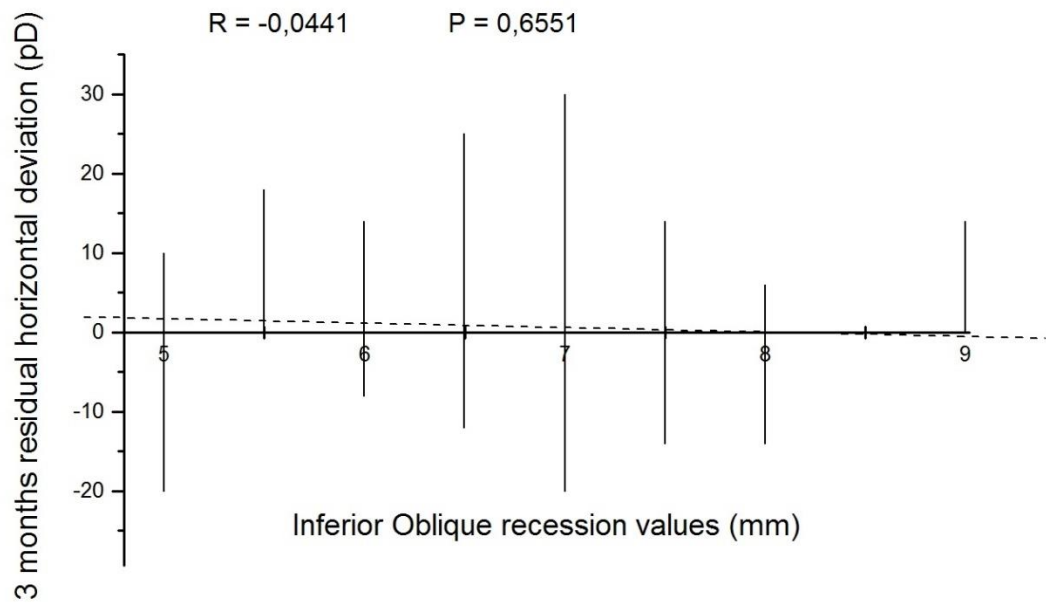
No significant correlations between LR resection entity and postoperative 3 months deviation was reported.

Fig 7B Correlation between LR resection (mm) and 10 years horizontal residual deviation (PD)



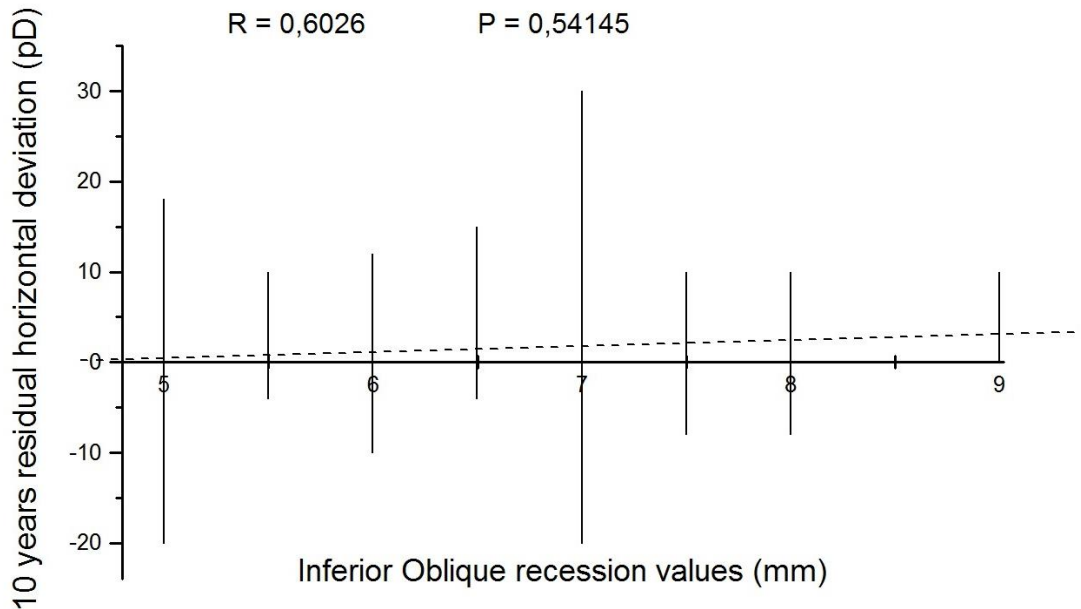
No significant correlations between LR resection entity and postoperative 10 years horizontal deviation was reported.

Fig 8A Correlation between IO recession (mm) and 3 months horizontal residual deviation (PD)



No significant correlations between mean IO recession entity and postoperative 3 months horizontal deviation was reported.

Fig 8B Correlation between IO recession (mm) and 10 years horizontal residual deviation (PD)



No significant correlations between IO recession entity and postoperative 10 years horizontal deviation was reported.

No complications such as scleral perforation, anterior segment ischaemia, postoperative infections were recorded.

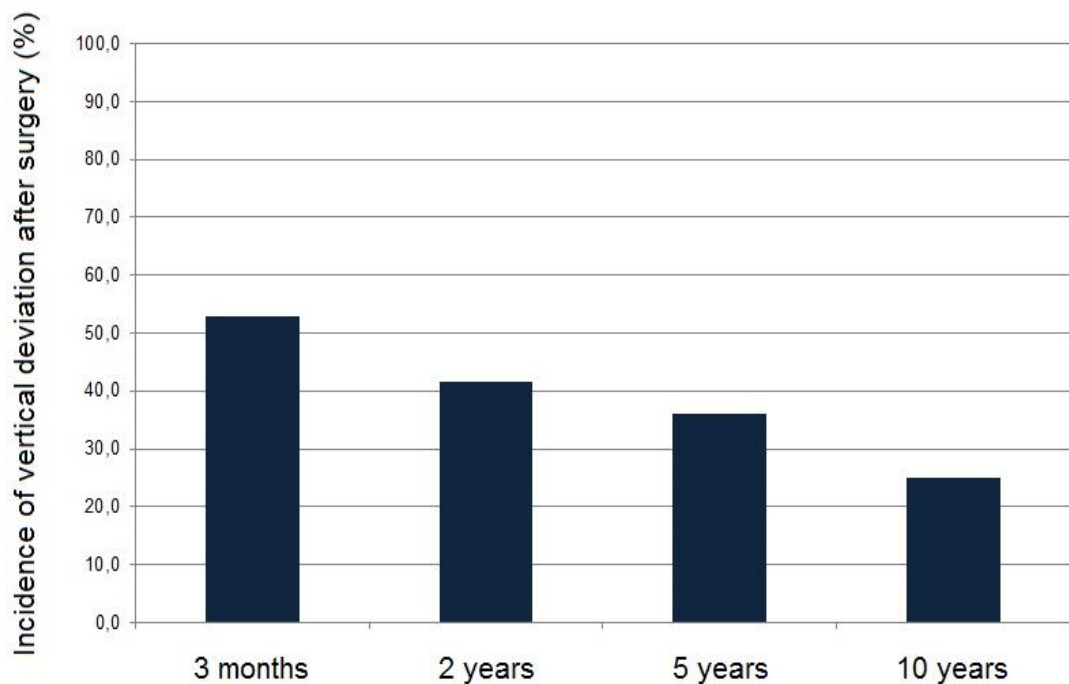
No patients underwent reoperations; as previously stated, patients who underwent reoperations were excluded from the present study.

Considering follow-up of vertical deviation , Tab 5 A-B shows all postoperative vertical data.

Tab 5A. Post-operative vertical data in primary position

		Before surgery	Follow-up after surgery			
			3 months	2 years	5 years	10 years
< 8 ^Δ	n (%)	6 (100)	36 (63,2)	27 (60)	36 (92,3)	21 (77,8)
≥ 8 ^Δ	n (%)	0 (0)	21 (36,8)	18 (40)	3 (7,7)	6 (22,2)

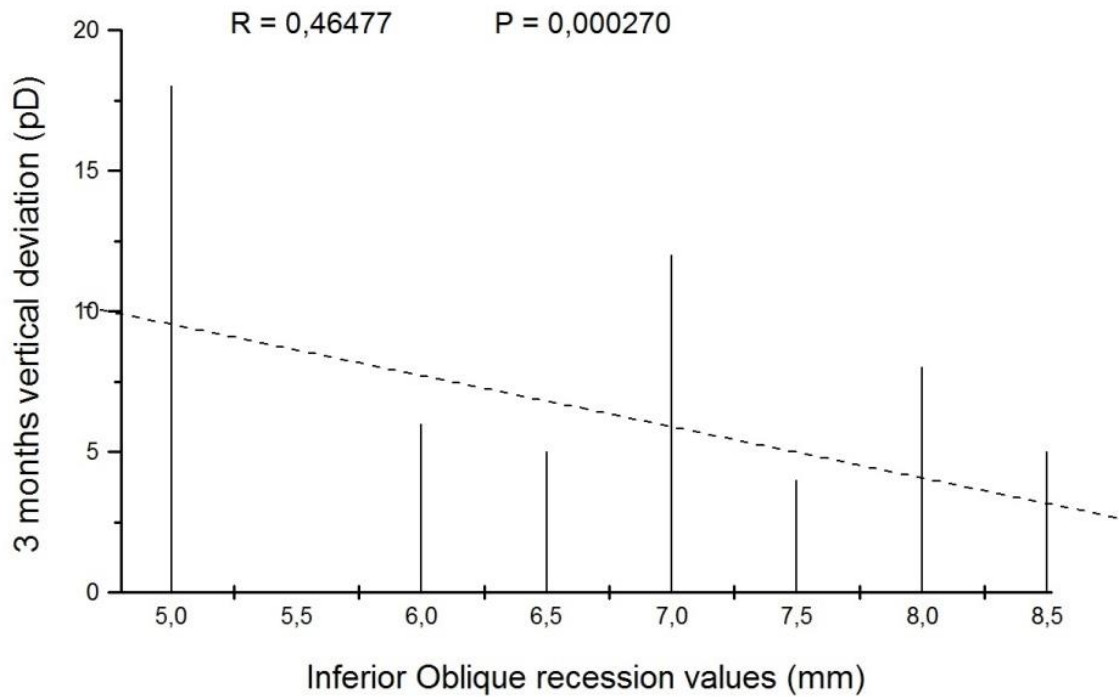
Tab 5B. Post-operative vertical data



Mean values of vertical deviation 3 months after surgery show an improvement trend 2 years postoperatively ($p < 0.01$) and remains stable afterwards.

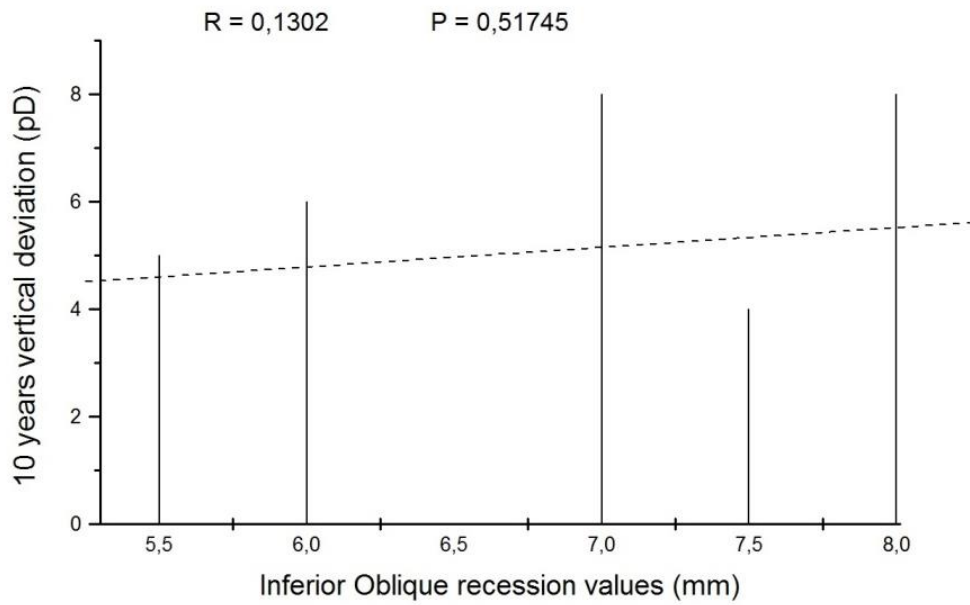
10 years after surgery, 6 patients (22,2 %) showed a vertical deviation $\geq 8^{\Delta}$.

Fig 9A Correlation between IO recession (mm) and 3 months postoperative vertical deviation (PD)



Significant correlation between IO recession entity and postoperative 3 months vertical deviation was reported. A greater IO recession entity was associated with a smaller vertical deviation in primary position, at 3 months postoperative. These data need further evaluations in future researches.

Fig 9B Correlation between IO recession (mm) and 10 years postoperative vertical deviation (PD)



No significant correlation between IO recession entity and postoperative 10 years vertical deviation was reported.

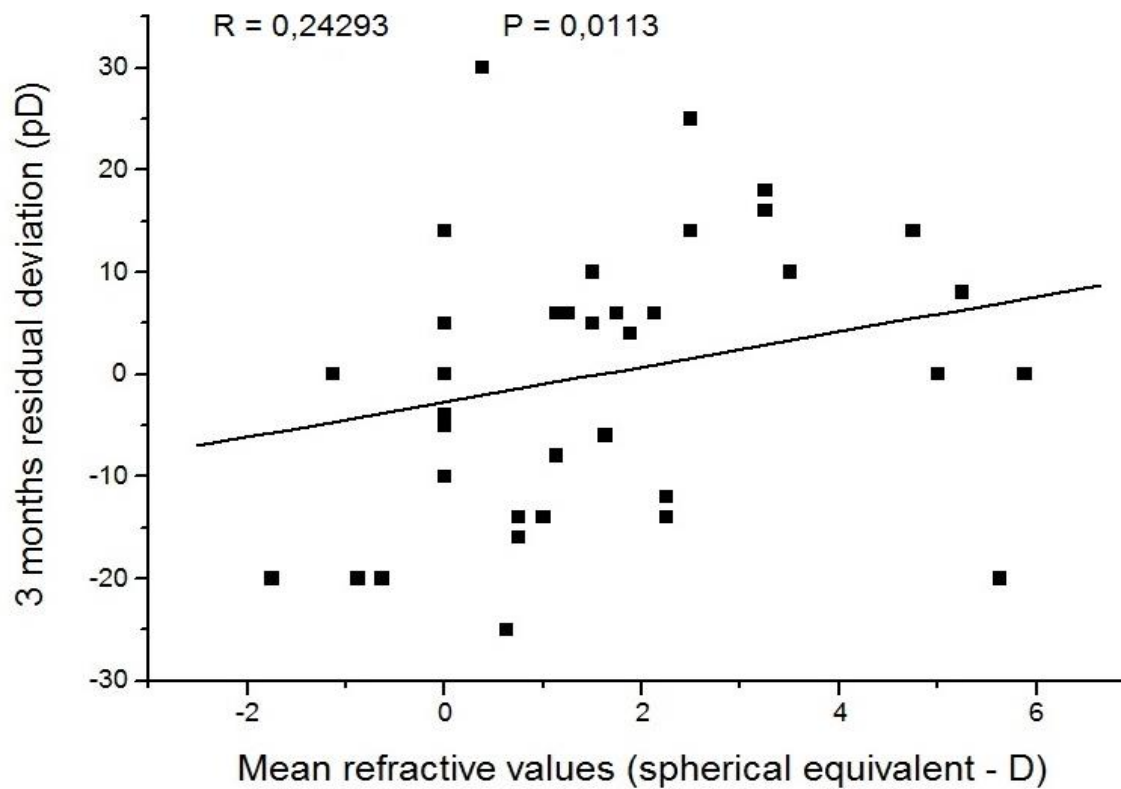
Postoperative spherical equivalent at last follow-up is reported in Table 6.

Tab 6. Spherical equivalent at last follow-up

	RE	LE
SE Range	-2.50 to +5.75	- 1 to +6.25
Neutral SE	30	24
Negative SE	12	9
Positive SE ≤ + 1.50	24	24
Positive SE > + 1.75 < + 3.25	24	33
Positive SE ≥ + 3.50	18	18
Total	108 eyes	108 eyes

Mean refractive values related to residual deviation are shown in Fig 10.

Fig 10.



There is a correlation between 3 months postoperative deviation and refraction ($p < 0.05$).

Number of myopic patients is inappropriate to compare the two groups. Nevertheless, by examining the graph and the significance results, we can suppose there may be a trend of residual esotropic deviation related to higher hypermetropia / accommodative factors playing an important role in surgical result .

Correlation is lost at 10 years follow-up.

Concerning preoperative sensorial evaluation, data were not recordable in 105 patients, while 3 patients showed exclusion.

Postoperative data report alternative exclusion in 9 patients , RE exclusion in 15 patients , LE exclusion in 15 patients , while a certain degree of binocular vision in 41 patients. In 28 cases data are missing.

Occlusion treatment was reported to be performed in 54 patients and not reported in 54 patients.

Concerning BCVA for distance, it was reported preoperatively only in 9 children (18 eyes) , RE range 0,22 – 0,04 LogMAR and LE range 0,40 – 0,04 LogMAR .

Postoperatively, BCVA for distance was recorded in 75 children (150 eyes) , both RE and LE range 0,30 to -0,14 LogMAR) (Tab 7).

BCVA Range 0,30 to -0,14 LogMAR	RE	LE
0.3 logMAR to 0.2 logMAR	21 eyes	15 eyes
0.1 logMAR to 0 logMAR	12 eyes	24 eyes
Equal or better than 0 logMAR	42 eyes	36 eyes
Total	75 eyes	75 eyes

Tab 7 . Postoperative BCVA

DISCUSSION

Non-Surgical Interventions - Use of Botulinum Toxin

Whilst surgical intervention for IE still seems to be the initial method of choice for the majority, a non-surgical intervention, (botulinum toxin) to alter ocular muscle alignment was first reported in Scott¹⁰.

After this, Scott¹⁷ reported the results of botulinum toxin (BT) on a group of IE patients. The study found that 65% of this group achieved alignment to within 10 pD of orthotropia, with just over two years follow-up with no adverse effects (there was no mention of binocular state). This was in contrast to Biglan's publication a year earlier, which concluded that BT was not as successful as surgery for IE treatment¹⁸.

Following this, Ing in 1992¹⁹, looked at a group of 49 patients, three years after alignment with botulinum to try and determine the effectiveness of BT in achieving binocularity. He found positive binocularity (sensory and motor fusion) in approximately half of this group. He then compared his results to another group of patients with IE aligned by surgery, concluding that botulinum was less effective than surgery in establishing binocularity ($P < 0.005$).

Mc Neer published in 1994 his results of 57 IE patients²⁰, all of whom received bimedial rectus botulinum injections. The authors concluded that, for the purpose of improving ocular alignment, BT was an effective therapy, reducing the squint angle, both in patients under the age of 12 months and in those under the age of 24 months. The follow-up period was a minimum of 12 months.

In 2010, a single-centre, prospective, non-randomised comparative study²¹ concluded demonstrated that surgery was more successful than BT in the treatment of large angle IE; however in smaller angle squints (< 30 pD to 35pD) it was found to be comparable to surgery. The study shows that botulinum toxin may be considered only for with small- to moderate-angle infantile esotropia.

Gursoy and coworkers²² performed a retrospective review of 56 patients treated before 24 months with either botulin toxin or bilateral MR recession and at least 48 months of follow-up. The surgical dose was chosen according to Helveston. Botulin toxin treatment dosage was 4.0 units on initial injection and 2.5 units for reinjection. Success was defined

as alignment within 10 pD of orthotropia at the time of last examination with up to three injections or a single surgical procedure. Although there was no difference in binocular alignment with botulinum toxin versus surgical treatment, 77 % of the surgical group and 68% of the toxin group had success; stereopsis was essentially equal between the groups. The average number of injections in the successfully treated group was 1.4 and transient ptosis was reported in 32 % of the yes. Gursoy reported, in 2012, no difference in binocular alignment with BT versus surgery and proposed that BT may be considered a primary treatment for IE ²².

BT complications, such as ptosis, vertical deviation, diplopia and subconjunctival hemorrhage are reported to be between 24 and 55% in a recent Cochrane review by Rowe and Noonan ²³.

The role of BT prior to surgery was retrospectively evaluated ²⁴. It was found to be effective in reducing the amount of further horizontal surgery needed. However, the authors found that in children under 18 months, injection of five units of botulinum induced unbalanced DVD.

Botulinum toxin has also been used in addition to surgery (augmented surgery).

Lueder suggests that, especially in large angle deviations, augmentation with BT may be more effective than bimedial recessions alone^{25,26}. In 2012 he retrospectively reviewed 23 patients with large angle IE (greater than 65 pD) treated with bilateral MR recession augmented with BT with at least 3-years of follow-up²⁶. Their treatment consisted of bilateral MR recession with augmentation of 1.25 units in one muscle for patients with 65-70 pD of ET , while 2.5 units in patients with ET > 70 pD. Treatment success was recorded in 74% of patients with a mean follow-up of 6.6 years.

Furthermore, botulinum toxin has been shown, by randomised trials, to be a good alternative to surgery for IE re-treatment, being equally successful as surgery in achieving binocularity (sensory and motor fusion - not stereopsis), if carried out within six months of surgery ²⁷.

Donahue ²⁸ reports, in a recent review in 2013, the use of BT into the MR of patients who had already undergone standard incisional MR recessions for esotropia but still have a residual deviation.

Studies of non-surgical interventions continue to be undertaken and published, mainly on the use of botulinum toxin. However, although Mc Neer and Tucker state that BT is

their primary treatment for IE ²⁹, the current use of BT as a primary intervention for IE remains limited, when compared to surgical intervention.

Age at intervention

The advantages and disadvantages of surgical intervention at an “early” (< 2 years of age) or “late” (> 2 years of age) stage have been debated in the literature.

Both timings show advantages and disadvantages ¹⁶, some are highlighted below:

Early surgery (< 2 years of age)

Advantages: Better potential for gross binocular vision, reduced muscle contraction

Disadvantages: Difficulty in obtaining reliable and accurate measurements, may increase the risk of amblyopia, higher reoperation rate

Late surgery (after age 2)

Advantages: Amblyopia management easier, more reliable measurements and evaluation of vertical deviations and muscles hyperfunctions

Disadvantages: Reduced potential for binocularity, muscle contracture can lead to mechanical component to squint

Prospective cohort studies have found that surgical alignment is associated with better stereopsis (which is considered the ‘gold’ standard in binocularity) in patients who received treatment within the first 24 months of life (early surgery) ^{30,31}.

According to Cerman ³², surgery for IE is most likely to result in measureable stereopsis if patient age at alignment is not more than 16 months. There was a statistically significant inverse correlation between age at surgery and final stereopsis ($r = 0.494$, $P = 0.002$). There was a significant difference at mean age at surgery between patients having stereopsis better than 1000 arc/sec and those having no stereopsis ($P = 0.002$).

Wright³³ suggested even earlier surgery, between the age of 2.5 and 3 months, resulting in good binocularity, in agreement with Helveston’s proposal of ‘ultra-early surgery’ between four and six months.

Based on these reports, Ing performed a multi-centre study analyzing IE patients operated on at six months of age or earlier³⁴. He included 16 IE patients that had been surgically aligned at an average age of 4.2 months, all with a minimum of 4 years follow up. Ing concluded that surgery before six months of age did not lead to a better binocularity compared to patients aligned at six months of age. Interestingly, he concluded that binocularity remains an elusive target and a rare outcome of treatment for IE.

Birch, in 2006, looked at the long-term motor and sensory outcomes of children operated on by the age of six months and concluded that early surgery was associated with a higher prevalence of fusion and stereopsis than surgery performed after this age³⁵.

The early versus late strabismus surgery study (ELISSS)³⁶ was a large multi-centre, non-randomised trial, involving 58 clinics, who recruited 231 children IE the “early” surgery group (6 to 24 months) and 301 in the “late” group (32 to 60 months). This study found that children operated on early had better “gross” stereopsis at age 6; however they had been operated on more frequently compared to the late group. There was no significant difference in the angle of the strabismus between the two groups. In 2010, the ELISSS study published further results³⁷, concluding that the benefit of early surgery for gross binocular vision, is balanced by a higher re-operation rate and an occasional child being operated on that would have had a spontaneous decrease without surgery. In another research, Polling³⁸ evaluated children who had late surgery (aged 3 to 8 years) and concluded that 38.4% of these had some degree of gross binocular vision postoperatively.

Gerth³⁹ looked at the effects that the timing on surgery for IE has on cortical visual motion processing (by measuring visually evoked potentials), concluding that early surgery (which is defined by the authors “as at or before 11 months of age”) promotes the development of cortical visual motion processing compared to surgery after this age. In a recent work by our team⁴⁰, sensory status was evaluated in patients who underwent surgery at different ages, in a retrospective study. Setting of the study is the Ophthalmology Department of a Teaching Hospital. Different clinical characters were analyzed pre and postoperatively; 9 different surgeries were performed. 188 patients presented valid postoperative sensorial data, divided in 2 groups: surgery at ≤ 2 years

(n=69) or > 2 years (n=119). Sensory status was dichotomized in binocular single vision (BSV) and exclusion. Univariate differences were assessed with the chi-square test (or Fisher exact test). To identify the independent role of factors associated with the sensory status, all variables showing in univariate analyses a significant association ($p < 0.05$) with the outcome variable, were entered into a multivariate logistic regression model. All statistical tests were two-sided.

Results from our multivariate analysis confirmed that children operated > 2 years of age were 0.4 times less likely to obtain BSV compared with children operated at ≤ 2 years (AOR. 0.38, 95% C.I. 0.17 – 0.89, $p = 0.025$).

Patients operated on by OO MR recession + OO LR resection + OO IO recession and anteriorization (intervention type 6) were about 11 times more likely to have BSV than those by OO rec.MR + unilateral res. LR (operation type 2); AOR.: 10.67, 95% C.I.: 1.34 – 85.29, $p = 0.026$).

Twenty-nine patients (12.1%) operated at ≤ 2 years of age underwent a reoperation, compared to 33 (8.6%) who underwent surgery after 2 years ($p > 0.05$).

In conclusion, our findings suggest to perform EIE surgery between age 1 and 2 and, when indicated, to prefer a 6 muscle approach, in order to achieve a better sensory function.

These data confirm the importance of an approach before age 2 in order to obtain a better degree of binocular vision.

Studies have also looked at the effect of surgery not only on vision, but also on neuromotor development. Both Drover⁴¹ and Caputo⁴² have conducted works concerning the relation between congenital squints and surgery. Both studies concluded that squint surgery is beneficial to both, motor function and development. This is an area for further research.

According to Shin, in 2014, evaluating DVD after IE correction, surgical IE intervention prior to 24 months of age decreased the incidence of spontaneous DVD, especially in large angle IE⁴³.

The actual aims and outcomes of treatment are to improve ocular alignment and achieve some degree of binocularity.

Most authors agree about the ocular alignment and aim for alignment within 10pD of orthotropia. However, claims of positive demonstrable binocularity after intervention vary widely.

This is most likely due to the methods used to assess / confirm the presence of binocularity and the fact that definition of positive stereopsis and binocular vision can vary. The ELISSS study used the term “gross” stereopsis/ binocularity - very few patients in either arms of this trial actually achieved better than this level i.e. good quality binocularity.

Finally, there seems to be general agreement that any intervention should be earlier rather than later; however gross binocular vision still seems possible in those receiving late intervention.

The above highlights that the current literature in the area of timing of intervention is still conflicting

Surgical techniques

Studies have found that a constant ET of > 40 pD in patients aged two to four months did not spontaneously resolve³¹ or had a low likelihood of doing so⁴⁴.

Most authors agree that surgical intervention is necessary to treat IE.

Concerning different surgical techniques, many authors have tried to finalize which approach is to be preferred.

Long back, in 1976, Arnoult and coworkers⁴⁵ looked retrospectively at two groups of patients; group 1 had undergone bimedial recessions, group 2 unilateral surgery with LR resection and MR recession. Postoperatively, the average angle of each group was found to be the same; however, no statistical analysis was documented.

More recently, the traditional surgical approach, according to several authors, is considered bilateral MR recession^{13, 14, 46- 51}.

Data from physiology are hereby reported, in order to better understand the unilateral or asymmetric recessions and the possible incomitances.

A muscle recession moves the muscle insertion to a new location closer to the muscle's origin creating muscle slack. Muscle slack created by a recession reduces muscle strength as per Starling's length tension curve. The initial slackening of muscle fibers is taken up by fiber reorganization but there is probably a persistent change in both the recessed muscle and the antagonist.

Surgical charts on the amount of recession for a specific deviation reflect the exponential character of the length tension curve. For example, each 0.5 mm of a bilateral medial rectus recession will correct approximately 5 prism diopters (PD) of esotropia up to a recession of 5.5 mm. However, after 5.5 mm of recession, each additional 0.5 mm of recession results in 10 PD of correction. Clinically, this is important, as we must be extremely careful when measuring large recessions because relatively small errors in measurement will result in large errors in eye alignment. An inadvertent over recession of only 1.0 mm on a planned 6.0 mm bilateral medial rectus recession could result in a 20 PD overcorrection.

A unilateral rectus muscle recession will induce incomitance, as rectus muscle recessions have more of an effect in the field of action of the muscle.

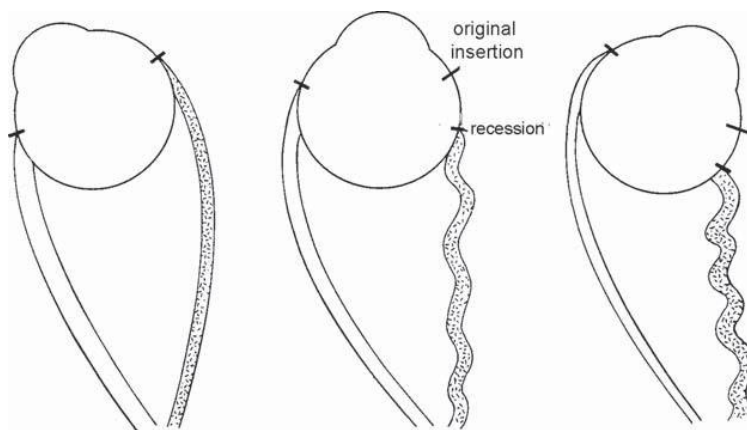


Fig 11.

Note that when the eye rotates towards the recessed muscle (Fig 11, *right drawing*), the moment arm shortens and muscle slack increases. This results in progressive weakening of the rotational force as the eye turns towards the recessed muscle. In contrast, on eye rotation away from the recessed muscle (Fig 11, *left drawing*), the moment arm is at full length, and muscle slack is reduced. In addition, on eye rotation away from the recessed

muscle, the recessed muscle is inhibited (Sherrington's law of agonist and antagonist) so the effect of the recession is minimal.

For example, a right MR recession will produce an exoshift in primary position and a larger exoshift in left gaze with very little exoshift in right gaze.

Therefore, according to physiology, Wright reports that unilateral or asymmetric recession will induce incomitance, whereas bilateral symmetrical recessions will produce a comitant result.

For this reason, MR recessions, when performed, need to be bilateral and symmetrical.

Helveston and coworkers performed a bilateral MR recession of 8.0 to 10.0 mm (measured from limbus); their study showed IE can be treated in the 4-month old with this approach, but this does not ensure continued alignment⁵².

A randomized comparison of graded versus standard bimedial recessions⁵³, concluded that standard 10.5 mm bimedial recessions achieved a better final ocular alignment.

A trial of severing the check ligaments and intermuscular membranes on the medial recti during surgery found no significant difference between the two groups⁵⁴.

Concerning a two muscle approach, recently Y-splitting recession surgery has also been suggested. Badawi and Hezagy published a comparative study of Y-split recession versus bilateral medial rectus recession for surgical management of IE. They have studied 30 patients affected by large angle IE. They divided patients into Group A, which underwent bilateral medial rectus (BMR) recession and Group B, which underwent bilateral Y-split MR. Their results have shown that, although the Y-splitting technique is more difficult and time consuming, both procedures are effective and have shown comparable results for the correction of horizontal deviation <70 PD⁵⁵.

On the other hand, different studies suggest that a three horizontal muscle surgery (bilateral MR recession with unilateral LR resection) is associated with a high success rate^{12, 15, 56}.

Concerning three muscles approach, Forrest published, in 2003, the long term outcomes of 49 patients who underwent three muscle surgery for IE and concluded that graded, three horizontal muscle surgery has a high success rate in attaining good ocular alignment⁵⁷.

Nevertheless, Poling and colleagues³⁸, in their randomized trial comparing bilateral recessions to unilateral recession-resection surgery for IE, concluded that there is no statistically significant difference in degree of alignment achieved.

Other authors also suggest a three muscle surgery (bilateral MR recession and LR plication), preferring a LR plication to LR resection⁵⁸.

Few main studies in the recent literature retrospectively looked at surgical outcomes. Bayramlar performed a retrospective review of 18 patients with IE with an angle greater than 55 pD, who underwent bilateral MR recession and LR resection in non dominant eye¹⁵. Median age was 22 months (10 – 168); orthotropia to within 10 pD or less was achieved in 78 % of patients with a median follow-up of 32 months (5-63 months). No overcorrection occurred and 22% had reoperation for residual ET. Nevertheless, this study shows some limitations, including the retrospective nature, the extremely low number of patients, no standard surgical dosage was used, cyclovertical procedure performed at the same time in only one patient and very large of age of operation.

Recently, authors have suggested to perform specific approaches, according to the different preoperative angle.

In cases of small preoperative deviations, majority of authors suggest the double MR recession, possibly associated with unilateral LR resection.

Concerning large-angle esotropia, optimal surgical technique is still extremely controversial.

According to some authors, surgery can be performed on 2 muscles, with a large bimedial recession, even in great angle Infantile Esotropia^{57, 59-62}.

A seven-millimeter bilateral MR recession is considered a possible approach as alternative to multiple muscle procedures in the initial treatment of large-angle EIE, leaving the lateral rectus muscles unoperated for future surgeries, if necessary^{13,63}.

Authors who support large recession, such as Forrest⁵⁷, claim that in their cases this surgical choice led to a reduction in re-interventions number, obtaining eye alignment in over 70% of cases.

Vroman and coworkers⁶⁴ report that the success rate for ocular realignment in patients with EIE by using bilateral MR recession did not appear to diminish when applied to deviations greater than 50 pD, as compared with smaller angle deviations. Similarly, according to Damanakis opinion¹⁴, surgery on 3 or 4 horizontal rectus muscles may be unnecessary in the treatment of patients with very large angles.

On the other hand, surgery can also be performed on 3 or 4 horizontal recti.

Nevertheless, some authors are concerned about possible complications of a multiple surgery, such as anterior segment ischemia.

The anterior segment is fed by seven anterior ciliary arteries and two long posterior ciliary arteries, with approximately 50% perfusion from posterior ciliary arteries and 50% from anterior ciliary vessels. Two anterior ciliary arteries course through each rectus muscle, except for the lateral rectus muscle, which has only one artery. Anterior to the rectus muscle insertions, the anterior ciliary arteries branch to form the episcleral limbal plexus. This, in turn, connects to the major arterial circle of the iris, which is also fed by the two long posterior ciliary arteries. The long posterior ciliary arteries penetrate the globe close to the equator at 3 o'clock and 9 o'clock and course anteriorly to anastomose with the anterior circulation (Fig 12).

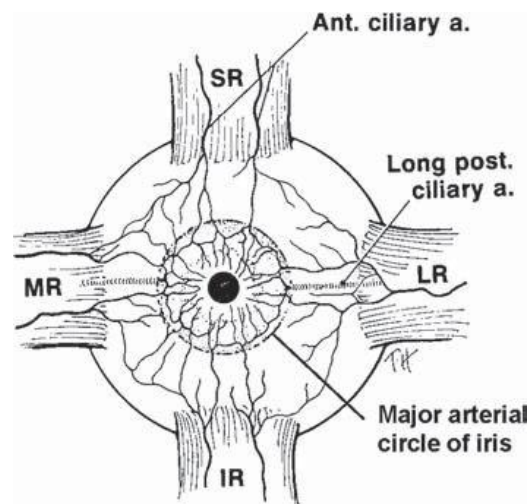


Fig 12

Disinserting a rectus muscle during strabismus surgery will interfere with the vascular supply to the anterior segment. Anterior segment ischemia is a well-known, albeit rare, complication of strabismus surgery. There is no formula for the number of rectus

muscles that can be safely detached, but once a muscle with its anterior ciliary arteries has been detached, the vessels do not reestablish perfusion to the anterior segment.

As a general rule, it is suggested not to detach more than two rectus muscles at one time, unless absolutely necessary.

For this reason, in infantile esotropia, performing a horizontal multiple approach (not involving both superior and inferior recti muscles) doesn't significantly increase the risk of anterior segment ischemia.

Based on previous reported data, in large angle infantile esotropia (≥ 60 PD), different authors suggest a three horizontal muscle surgery, with double MR recession and unilateral LR resection, appearing to have a good long term success rate without leading to high rates of either residual ET or consecutive XT ⁶⁵⁻⁶⁷.

Surgery can also be performed on 4 muscles (double MR recession with bilateral LR resection), in order to "distribute" the surgical entity on more muscles and avoid a maximal recession, leading to possible incomitances. We usually prefer this approach, "distributing" the surgical entity on more muscles; in our experience it leads to good long-term results.

According to our previous data, in small angle IE, an approach on few muscles seems indicated, while in large angle EIE a multiple muscles approach is to be suggested, leading to better postoperative motor outcomes .

Following data report our previous work ⁶⁸.

..previous data from our study group..

In a recent work from our team, we retrospectively reviewed IE children who underwent different surgical procedures, with at least 5 years of follow-up.

The aim of this retrospective study was a long-term evaluation of postoperative motor outcomes and the inferential analysis of strabismus surgery in infant eyes with IE.

576 patients were compatible with the criteria: confirmed EIE diagnosis, angle ≥ 30 pD, absence of associated ocular anomalies, onset by 6 months of age, absence of hyperopia > 3 Diopters, operation before age 4.

Preoperative deviation classes (30–40 pD, 41–59 pD, ≥ 60 pD) were established.

Different types of surgery were performed (bilateral MR recession, bilateral MR recession with unilateral LR resection, bilateral MR recession with bilateral LR resection with /without conjunctival recession, bilateral MR recession with IO anteriorization, bilateral MR recession with bilateral LR resection and IO anteriorization with /without conjunctival recession).

We evaluated results based on different postoperative angle at last examination. Surgical success was defined total success (orthotropia), partial success (within 10 pD of orthotropia), unsuccess (> 10 pD of deviation).

The sample included 576 patients (249 F and 327 M). Mean age at surgery was 2.7 ± 0.7 (1–4); 68 (11.8%) patients were operated after 3 years of age.

Surgery	n (%)	Age, mean \pm std. dev. (min – max) at 1 st surgery; years
Type 1: OO rec MR	6	
Type 2: OO rec MR + res LR	29 (5.0)	2.8 \pm 0.5 (2–4)
Type 3: OO rec MR + OO res LR	71 (12.4)	2.6 \pm 0.7 (1–4)
Type 4: OO rec MR + OO res LR + rec conj	29 (5.0)	2.9 \pm 0.6 (2–4)
Type 5: OO rec MR + rec-ap IO	19 (3.3)	2.5 \pm 0.5 (2–3)
Type 6: OO rec MR + OO res LR + rec-ap IO	156 (27.1)	2.9 \pm 0.6 (1–4)
Type 7: OO rec MR + OO res LR + rec conj + rec-ap IO	272 (47.2)	2.5 \pm 0.7 (1–4)
Total	576 (100)	2.7 \pm 0.7 (1–4)

Type 1 (OO rec MR) patients were excluded from the data analysis, due to too small sample for statistical evaluation.

Concerning the sample distribution: 210 patients (36.5%) had a deviation between 30 and 40 pD, 181 (31.4%) between 41 and 59 pD, while 185 children (32.1%) had a pre-operative angle ≥ 60 pD. The mean preoperative deviation was 49.8 ± 13.2 pD, ranging from 30 to 100 pD.

According to surgery type (Table on previous page) our patients showed greater frequency of type 7 (47.2%) and type 6 (27.1%) interventions while intervention 5 was the least frequent (3.3%), with different distribution in the different deviation classes.

Mean age at first surgery varied slightly according to surgical approach. Longitudinal data were analyzed using general linear mixed models stratified according to the class of pre-operative deviation. A random intercept and a random slope with time (in months) was assumed with an unstructured within subject correlation structure for repeated measurements.

Results

- In patients with preoperative angle ≤ 40 pD (Class 30–40 pD) a significant interaction effect for intervention by time ($F_{5,155.9} = 3.56$, $p = 0.004$) and a significant intervention effect ($F_{5,226.1} = 6.41$, $p < 0.001$) on residual deviation were observed; only the intervention 5 showed a residual deviation inside the limits of a partial success. The covariate of a second intervention was also observed to have a significant impact on residual deviation ($F_{1,161.4} = 80.44$, $p < 0.001$) with an average reduction of 17.4 pD (95% C.I. 13.6 pD; 21.3 pD).
- In Class 41 - 59, a significant interaction effect for intervention by time ($F_{4,166.7} = 5.16$, $p = 0.001$), intervention ($F_{4,178.1} = 2.48$, $p = 0.046$) and time ($F_{1,174.6} = 9.99$, $p = 0.002$) on residual deviation were observed; intervention 7 had the highest degree of stability, showing an outcome within the range of a partial success. The following covariates also had a significant impact on residual deviation: nystagmus ($F_{1,144.4} = 6.34$, $p = 0.013$) and lateral recti muscles hypofunction ($F_{1,149.6} = 28.93$, $p < 0.001$) causing, during 5 years follow up after the intervention, an average increase in the residual deviation of 4.8 pD (95% C.I. 1.1 pD; 8.5 pD) and 7.0 pD (95% C.I. 4.4 pD; 9.5 pD) respectively.
- In Class ≥ 60 pD no significant effect for intervention ($F_{4,213.9} = 0.74$, $p = 0.567$), time ($F_{1,169.5} = 0.33$, $p = 0.569$) or intervention by time ($F_{4,160.9} = 1.08$, $p = 0.368$) on residual deviation was observed. The covariate 'lateral recti hypofunction' was also observed to have a significant impact on residual deviation ($F_{1,152.8} = 7.07$, $p = 0.009$) with an average increase of 4.9 pD (95% C.I. 1.3 pD; 8.6 pD).

In our opinion, surgery on small number of muscles, in IE, might lead to an increase in surgical dosage (supramaximal recessions) with greater incomitances in lateral gaze positions. Therefore, we rarely perform only medial recti bilateral recession (type 1). In our cohort, 6 cases who had undergone this approach, operated before age 4, were

fulfilling all the inclusion criteria. Nevertheless these cases were not included in the analysis, due to too small group sample. Accordingly, type 2 and type 5 surgeries have been used by us less frequently, compared to other surgical options.

On the other hand, we believe that a multiple muscles approach can give the opportunity to reduce recessions and distribute them amongst all horizontal recti. A minimal and harmonious dosage may reduce the incidence of incomitances, with excellent results even in large esodeviations. When oblique muscle hyperfunction is also present, it is essential to carry out an inferior oblique muscle recession with anteriorization, in addition to horizontal surgery. No myotomies, myectomies or disinsertions were performed for cases with oblique dysfunction.

In order to correct hypertropia, in patients with DVD, a superior rectus recession can also be carried out. In our cohort, entity of DVD, when present, did not require an approach during first surgical procedure. Furthermore, all types of surgeries can also be associated with conjunctival recession.

Our inferential analysis results showed the distribution of confidence intervals during follow-up in the different deviation groups.

Regarding pre-operative deviations ranging between 30–40 pD, it is seen that during the 5 years follow-up, only the intervention 5 showed a residual deviation inside the limits of a partial success, while intervention 7 showed the worse results leading to a secondary XT.

Concerning deviations between 41 and 59 pD, intervention 7 had the highest degree of stability during the 5 year follow up, showing an outcome always within the range of a partial success. Partial success 5 years after surgery was also observed for intervention 3, despite showing exotropia during follow-up. Intervention 6 on the other hand, presented stability during the first year after surgery but was associated with residual ET at last follow-up.

In patients presenting preoperative angle ≥ 60 pD, during the whole follow-up period, intervention 3, 6 and 7 resulted in a residual deviation within the range of a partial success.

Thus, our inferential analysis allows us to suggest, in deviations ≤ 40 pD, a surgery performed only on two medial recti muscles (associated in our data with treatment of inferior oblique overaction). On the other hand, in small angle esotropia, an approach

on multiple horizontal muscles might lead to an increased risk of postoperative exotropia.

Furthermore, in children with a preoperative deviation ≥ 60 pD (the so-called “large angle esotropia”), in our data type 7 surgery was the most valid therapeutic approach showing greater stability of residual ocular deviation results over time.

We consider it essential, therefore, to recommend, where possible, in large angle esotropic children, a multiple muscle approach, while a less invasive approach in small angle deviations. Concerning reoperations, 9.9% of patients underwent re-operation. The frequency of reintervention on patients operated with type 5 is higher, relatively to operation type. This suggests that an approach including only MR and IO, without LR, might increase reoperative rate. Nevertheless these data are considered preliminary data and should be further analyzed in a statistical model.

Another important result concerns the importance of follow-up. In the past, authors suggested that residual deviation results, detectable in later stages, could be foreseen at 6 weeks follow-up.

Previous studies have reported higher rates of postoperative microtropia, with shorter postoperative durations^{69,70}. Reports with longer follow-up periods have fewer microtropic patients at the final follow-up examination. This finding underscores the importance of longterm follow-up, in order to define the evolution of congenital esotropia after surgical intervention. Our study amply demonstrated that our data show broad oscillations at different post-operative examinations, even though some values keep within defined intervals, underlining the importance of long-term follow-up. The main limitations of this study are the scarceness of analyzable data after 5 years postoperatively, the difficulties of comparing data at superimposable biological ages and the absence of analysis concerning visual acuity during follow-up.

According to these data, in patients presenting large angle IE, the most successful surgery, in terms of ocular deviation stability over the long period of observation, is double MR recession associated with double LR resection, together with IO recession and anteriorization

Furthermore, as previously reported, other data from our study group on sensorial evaluation in IE patients⁴⁰, also report that children who underwent intervention on 6 muscles (bilateral MR s recession, bilateral LR resection and IO recession +

anteroposition) were about more likely to have binocular vision than those operated on by bilateral rec. MR + unilateral res. LR.

Several studies have suggested different techniques for EIE treatment over the last 20 years, making efforts to define the best surgical procedure and timing of surgery.

According to Elliott review¹⁶, the available literature now contradicts previous suggestions that bimedial recessions is the surgical method of choice.

However, no method has a clear advantage compare to others. In fact there are multiple surgical techniques used to treat IE ¹¹.

Finally, as there are no randomized trials at present, it has not been possible to resolve the controversies regarding, non-surgical options, age of intervention and type of surgery in patients with infantile esotropia.

Based on our previous works and considering there is no clear evidence favouring one surgical technique over the others in IE, we have chosen to study, in the current work, a 6 muscles surgical approach.

IE patients with inferior oblique hyperfunction underwent multiple muscles surgery at different ages within the first 4 years of life, and report, as decribed, interesting results at long term follow-up.

CONCLUSIONS

A 6 muscles approach appears to be a valid surgical alternative in patients affected by IE with inferior oblique hyperfunction and lateral rectus pseudoparalysis; it is worth noting that, after a median follow-up of 10 years, 27,8% of patients appear orthotropic and 47,2 % show a deviation between -10 pD and +10 pD.

This technique, on selected cases with IO hyperfunction, performed ≤ 4 years of age, may lead to long-term success rate.

Our preliminary data also underline the extreme importance of long term follow-up (data at 3 months are different from results 10 years after surgery).

Main strengths of our study are the large EIE sample on 6 muscle surgery, a long term follow-up, the use of detailed measurements and standardized postoperative sensorial evaluations. Furthermore, all surgeries were performed by a single surgeon and follow-up evaluations conducted by same orthoptic team.

Nevertheless it shows some major limitations, underlining the retrospective design of our work. Uncomplete preoperative sensorial data as well as BCVA are reported, due to age and poor cooperation. Results concerning association between vertical deviation in primary position and IO recession/anteriorization should be further analyzed. A longer follow-up may be needed to evaluate long-term sensory results and reoperation rate in adult age.

In IE, in presence of horizontal angle associated with significant upshoot requiring surgery, we suggest not to postpone the approach on oblique muscles as a second surgery.

Finally, according to recent literature, there are currently no randomized trials on different surgical approaches for IE, although many authors have stated their varying preferences. A multicenter trial would be needed in order to determine which procedure is more effective.

REFERENCES

1. Kommerell G. Ocular motor phenomena in infantile strabismus. Asymmetry in optokinetic nystagmus and pursuit, latent nystagmus, and dissociated vertical divergence. In: Lennerstrand G, von Noorden GK, Campos EC editor(s). *Strabismus and Amblyopia*. London, UK: MacMillan Press, 1988:99-109.
2. Nixon RB, Helveston EM, Miller K, Archer SM, Ellis FD. Incidence of strabismus in neonates. *American Journal of Ophthalmology* 1985;100(6):798-801.
3. Friedman Z, Neumann E, Hyams SW, Peleg B. Ophthalmic screening of 38,000 children, age 1 to 2 1/2 years, in child welfare clinics. *JPOS* 1980;17(4):261-7.
4. Von Noorden GK. Current concepts of infantile esotropia. *Eye* 1988;2:343-357.
5. Vasseneix C, Retout A, Ducrotte D, Brasseur G. Infantile esotropia: comparison of surgery results when the intervention takes place before or after 30 months of age. *J Fr Ophtalmol* 2005;287,743-8.
6. Meyer K, Breitschwerdt H, Kolling GH, Simonsz HJ. The early vs late infantile strabismus surgery study: do sources for bias exist in this non-randomised trial? *Br J Ophthalmol* 1998;82:934-8.
7. Calcutt C. Infantile esotropia: Current concepts in aetiology and management. *British Orthoptic Journal* 1993;50:37.
8. Ing MR. Early surgical alignment for congenital esotropia. *Ophthalmology* 1980;90(2):132-5.
9. Helveston EM, Ellis FD, Plager DW, Miller KK. Early surgery for essential infantile esotropia. *JPOS* 1990;27(3):115-9.
10. Scott AB. Botulinum toxin injection into extraocular muscles as an alternative to strabismus surgery. *Ophthalmology* 1980;87(10):1044-9.
11. Hug D. Management of Infantile Esotropia. *Curr Opinion Ophthalmol* 2015. Jul; 26(5):371-4
12. Szmyd SM, Nelson LB, Calhoun JH, Sprall C. Large bimedial rectus recessions in congenital esotropia. *Br J Ophthalmol* 1985; 69:271274.
13. Weakley DR Jr, Stager DR, Everett ME. Seven-millimeter bilateral medial rectus recessions in infantile esotropia. *J POS* 1991, 28:113-115.

14. Damanakis A, Arvanitis P, Ladas I, Theodosiadis GP: 8 mm bimedial rectus recession in infantile esotropia of 80–90 prism dioptres. *Br J Ophthalmol* 1994;78:842–844.
15. Bayramlar H, Karadag R, Yildirim A, Oçal A, Sari U, Dag Y. Medium-term outcomes of three horizontal muscle surgery in large-angle infantile esotropia. *J Pediatr Ophthalmol Strabismus*. 2014 May-Jun;51(3):160-164.
16. Elliott S, Shafiq A. Interventions for infantile esotropia. *Cochrane Database Syst Rev*. 2013 Jul 29;7:CD004917
17. Scott AB, Magoon EH, McNeer KW, Stager DR. Botulinum treatment of childhood strabismus. *Ophthalmology* 1990;97 (11):1434–8.
18. Biglan AW, Bumstine RA, Rogers GL. Management of strabismus with botulinum toxin A. *Ophthalmology* 1989;96(7):935–43.
19. Ing MR. Botulinum alignment for congenital esotropia. *Transactions of the American Ophthalmological Society* 1992; 90:361–7.
20. Mc Neer KW, Spencer RF, Tucker MG. Observations of bilateral simultaneous botulinum injections in infantile esotropia. *JPOS* 1994;31(4):214–9.
21. de Alba Campomanes AG, Binenbaum G, Campomanes Eguiarte G. Comparison of botulinum toxin with surgery as primary treatment for infantile esotropia. *J AAPOS* 2010 Apr;14(2):111-6.
22. Gursoy H, Basmak H, Sahin A, Yildirim N, Aydin Y, Colak E. Long-term follow-up of bilateral botulinum toxin injections versus bilateral recessions of the medial rectus muscles for treatment of infantile esotropia. *J AAPOS*. 2012 Jun;16(3):269-73.
23. Rowe FJ, Noonan CP. Botulin toxin for the treatment of strabismus *Cochrane Database Sys rev* 2014;2:CD006499
24. Ruiz MF, Alvarez MT, Sanchez-Garrido CM, Hernaez JM, Rodrigues JM. Surgery and botulinum toxin in congenial esotropia. *Canadian Journal of Ophthalmology* 2004;39(6): 639–49.
25. Lueder GT, Galli ML. Effect of preoperative stability of alignment on outcome of strabismus surgery for infantile esotropia. *J AAPOS* 2008; 12(1):66-8.

26. Lueder GT, Galli M, Tychen L, Yildirim C, Pegado V. Long term results of botulin toxin-augmented medial rectus recessions for large-angle infantile esotropia. *AM J Ophthalmology* 2012;153:560-563
27. Tejedor J, Rodriguez JM. Early re-treatment of infantile esotropia: comparison of botulinum toxin and re-operation. *British Journal of Ophthalmology* 1999;83(7):783-7.
28. Donahue SP. Botulinum toxin treatment for esotropia. *Am Orthopt J.* 2013; 63: 29-31.
29. Mc Neer K, Tucker M. Letters to the editor. *J AAPOS* 2010;14(6):558.
30. Birch E, Stager D, Everett M. Random dot stereoacuity following surgical correction of infantile esotropia. *Journal of Pediatric Ophthalmology and Strabismus* 1995;32(4): 231-5.
31. Birch E, Stager D, Wright K, Beck R. The natural history of infantile esotropia during the first six months of life. *Journal of AAPOS* 1998;2(6):325-8.
32. Çerman E, Eraslan M, Öğüt MS. *J AAPOS*. The relationship of age when motor alignment is achieved and the subsequent development of stereopsis in infantile esotropia. 2014 Jun;18(3):222-5.
33. Wright KW, Edelman PM, McVey JH, Terry AP, Lin M. High grade stereo-acuity after early surgery for congenital esotropia. *Archives of Ophthalmology* 1994;112(7):913-9.
34. Ing MR. Outcome study of surgical alignment before six months of age for congenital esotropia. *Ophthalmology* 1995;102(12):2041-5.
35. Birch EE, Stager DR. Long-term motor and sensory outcomes after early surgery for infantile esotropia. *J AAPOS* 2006 Oct; 10(5):409-13
36. Simonsz HJ, Kolling GH, Unnebrink K. Final report of the early vs late infantile strabismus surgery study (ELISSS), a controlled, prospective, multicenter study. *Strabismus* 2005; 13(4):169-99.
37. Simonsz HJ, Eijkemans MJ. Predictive value of age, angle and refraction on rate of reoperation and rate of spontaneous resolution in infantile esotropia. *Strabismus* 2010;18(3): 87-97.
38. Polling JR, Eijkemans MJ, Esser J, Gilles U, Kolling GH, Schulz E, Lorenz B, Roggenkämper P, Herzau V, Zubcov A, ten Tusscher MP, Wittebol-Post D, Gusek-

- Schneider GC, Cruysberg JR, Simonsz HJ. A randomised comparison of bilateral recession versus unilateral recession-resection as surgery for infantile esotropia. *Br J Ophthalmol* 2009; 93(7):954–7.
39. Gerth C, Mirabella G, Li X, Wright T, Westall T, Colpa L, et al. Timing of surgery for infantile esotropia in humans: effects on cortical motion visual evoked responses. *Investigative Ophthalmology and Visual Science* 2008;49(8):3432-7.
 40. Magli A, Carelli R, Esposito F, Bruzzese D. Essential Infantile Esotropia: postoperative sensory outcomes of strabismus surgery. *Seminars in Ophthalmology*, in press 2016.
 41. Drover JR, Stager DR Sr, Morale SE, Leffler JN, Birch EE. Improvement in motor development following surgery for infantile esotropia. *J AAPOS* 2008;12(2):136–40.
 42. Caputo R, Tinelli F, Bancale A, Campa L, Frosini R, Guzzetta A et al. Motor coordination in children with congenital strabismus: effects of late surgery. *European Journal of Paediatric Neurology* 2007;11(5):285–91.
 43. Shin KH, Paik HJ. Factors influencing the development and severity of dissociated vertical deviation in patients with infantile esotropia. *J AAPOS*. 2014 Aug;18(4):357-61.
 44. Pediatric Eye Disease Investigator Group. Spontaneous resolution of early-onset esotropia: Experience of the congenital esotropia observational study. *American Journal of Ophthalmology* 2002;133(1):109–18.
 45. Arnoult JB, Yeshurun O, Mazow ML. Comparative study of the surgical management of congenital esotropia of 50 prism dioptres or less. *Journal of Pediatric Ophthalmology* 1976;13(3):129–31
 46. Ing M, Costenbader FD, Parks MM, Albert DG: Early surgery for congenital esotropia. *Am J Ophthalmol* 1966, 61:1419–1427.
 47. Fisher N, Flom MC, Jampolsky A. Early surgery of congenital esotropia. *Am J Ophthalmol* 1968, 65:439–443.
 48. Helveston EM, Patterson JH, Ellis FD: En bloc recession of medial recti for concomitant Esotropia. *Proceedings of the New Orleans Academy of Ophthalmology*. St Luis, C.V: Mosby Co; 1978:130–243.

49. Tran HM, Mims JL, Wood RC. A new dose–response curve for bilateral medial rectus recessions for infantile esotropia. *J AAPOS* 2002, 6 (2):112-9.
50. Keskinbora KH, Pulur NK. Long-term results of bilateral medial rectus recession for congenital esotropia. *JPOS* 2004, 41:351–355.
51. Nucci P, Serafino M, Trivedi RH, Saunders RA. One-muscle surgery in small angle residual esotropia. *JAAPOS* 2007, 11:269–272.
52. Helveston EM, Neely DF, Stidham DB, Wallace DK, Plager DA, Sprunger DT. Results of early alignment of congenital esotropia. *Ophthalmology* 1999; 106(9): 1716-26
53. Kushner B, Morton G. A randomized comparison of surgical procedures for infantile esotropia. *AM J Ophthalmology* 1984;98(1):50-61
54. Friendly DS, Parelhoff ES, McKeown CA. Effect of severing the check ligaments and intermuscular membranes on medial rectus recessions in infantile esotropia. *Ophthalmology* 1993;100(6):945–8.
55. Badawi N, Hegazy K. Comparative study of Y-split recession versus bilateral medial rectus recession for surgical management of infantile esotropia. *Clin Ophthalmol.* 2014 May 23;8:1039-45.
56. Chatzistefanou KI, Ladas ID, Droutsas KD, Koutsandrea C, Chimonidou E. Three horizontal muscle surgery for large-angle infantile or presumed infantile esotropia: long-term motor outcomes. *JAMA Ophthalmol.* 2013 Aug;131(8):1041-8.
57. Forrest MP, Finnigan S, Gole GA. Three horizontal muscle squint surgery for large angle infantile esotropia. *Clinical and Experimental Ophthalmology* 2003;31(6):509–16.
58. Sturm V, Menke MN, Jaggi GP, Wandernoth P, Kunz A. Three horizontal muscle surgery for IE and decompensated microtropia. *Klin Monbl Augenheik* 2015 Apr; 232(4) 446-51.
59. Helveston EM, Ellis FD, Schott J, Mitchelson J, Weber JC, Taube S, Miller K: Surgical treatment of congenital esotropia. *Am J Ophthalmol* 1983, 96:218–228.
60. Weakley DR, Parks MM: Results from 7-mm bilateral recessions of the medial rectus muscles for congenital esotropia. *Ophthalmic Surg* 1990,21:827–830.

61. Tolun H, Dikici K, Ozkiris A. Long-term results of bimedial rectus recessions in infantile esotropia. *J POS* 1999, 36:201–205.
62. Altintas AK, Yilmaz GF, Duman S. Results of classical and augmented bimedial rectus recession in infantile esotropia. *Strabismus* 1999,7:227–236.
63. Prieto-Diaz J. Large bilateral medial rectus recession in early esotropia with bilateral limitation of abduction. *J POS* 1980, 17:101–105.
64. Vroman DT, Hutchinson AK, Saunders RA, Wilson ME: Two-muscle surgery for congenital esotropia: rate of reoperation in patients with small versus large angles of deviation. *J AAPOS* 2000, 4:267–270.
65. Edwards W, Moran CT, Askew M: Statistical analysis of esotropia surgery. *J Pediatr Strabismus* 1973, 10:256–266.
66. Louwagie CR, Diehl NN, Greenberg AE, Mohny BG: Long-term follow-up of congenital esotropia in a population-based cohort. *JAAPOS* 2009, 13:8-12.
67. Camuglia JE, Walsh MJ, Gole GA: Three horizontal muscle surgery for large-angle infantile esotropia: validation of a table of amounts of surgery. *Eye* 2011, 25:1435-1441.
68. Magli A, Carelli R, Matarazzo F, Bruzzese D. Essential infantile esotropia: postoperative motor outcomes and inferential analysis of strabismus surgery. *BMC Ophthalmol.* 2014 Mar 25;14:35.
69. Shaully Y, Prager TC, Mazow ML. Clinical characteristics and long-term postoperative results of infantile esotropia. *Am J Ophthalmol* 1994, 117:183-189.
70. Maruo T, Kubota N, Sakaue T, Usui C. Esotropia surgery in children: long term outcome regarding changes in binocular alignment; a study of 956 cases. *Binocul Vis Strabismus Q* 2000, 15:213–220.